CHAPTER

11

Physical Assessment

LEARNING OBJECTIVES

1. Outline the essential elements obtained from a health history.
2. List the four techniques of physical assessment.
3. Demonstrate six steps of the focus assessment.
4. Describe the abnormal manifestations associated with each specific body system for one client with whom you are familiar.
5. List four normal responses that determine the client's level of consciousness.
6. Describe four abnormal responses in pupil assessment.
7. State three assessment components of the skin.
8. Describe normal and abnormal lung sounds.
9. Outline the steps of breast assessment.
10. Identify the four areas for heart sound auscultation.
11. List at least five essential elements included in a mental status assessment.
12. Compare and contrast three elements of the antepartum obstetrical assessment.
13. Relate the elements of a "9" score on the Apgar test.
14. Describe basic components of a pediatric physical assessment.

ASSESSMENT

Basic assessment discussed in this chapter can be performed in less than 10 minutes using a stethoscope, penlight, reflex hammer, your hands, and observational skills. Although you may not be able to perform assessment rapidly at first, you will have many opportunities to practice your skills, because every client should be assessed at least once a shift.

While interviewing the client, note such characteristics as hair, skin, posture, facial expression, and body language—in other words, the general appearance of the client. Then proceed with a head-to-toe systems assessment using the four techniques of assessment: inspection, palpation, percussion, and auscultation. This IPPA sequence is used for all systems except for the abdominal assessment, which requires auscultation *before* palpation and percussion. Palpation and percussion are performed using fingers and hands to assess abnormalities of sound, such as vocal fremitus, enlarged organs, organ displacement, and chest expansion. Auscultation is accomplished by using a stethoscope to listen to breath, heart, and bowel sounds. Observe the client's response as each system is assessed.

EQUIPMENT

The stethoscope is the primary instrument used for assessment. Remember that any movement of the tubing or chest piece by clothing or hands can cause extraneous noise that obliterates the sounds you want to hear. The diaphragm piece should be applied firmly to the skin. It enhances high-pitched sounds (breath sounds, normal heart sounds, bowel sounds). The bell piece should be placed very lightly to pick up low-pitched sounds, such as vascular sounds and abnormal heart sounds. If the bell is pressed firmly, it stretches the skin and acts as a diaphragm. Other instruments used include the penlight, reflex hammer, ophthalmoscope, otoscope, and tuning fork.

HEALTH HISTORY

A total client assessment begins with a nursing health history. Using open-ended questions such as "Tell me about . . . ," collect data about past health conditions, current problems, and present needs. The information is obtained through objective (observed) and subjective (stated by client) data collection.

Information obtained from the interview and the physical assessment constitutes the basis for identifying nursing diagnoses and establishing the individualized client care plan. A complete health history includes the following elements:

- *Biographic information:* age, sex, educational level, marital status, living arrangements.
- *Chief complaint:* condition that brought client to health care facility; reason for visit; any recent changes.
- *Present health status or illness:* onset of the problem; clinical manifestations, including severity of symptoms; pain characteristics if present.
- *Health history:* general state of health, past illnesses, surgeries, hospitalizations, allergies, over the counter (otc's) medications, herbal supplements, current medications, and general habits such as smoking, alcohol consumption, or recreational drug use.
- *Family history:* age and health status of parents, siblings, and children; cause of death for immediate family members.
- *Psychosocial factors, lifestyles:* cultural beliefs that influence health management; religious or spiritual beliefs.
- *Nutrition:* dietary habits, preferences, or restrictions.
- *Domestic violence:* (JCAHO requirement).

NURSES' ROLE

The nurse's role in obtaining a health history and completing a physical assessment has expanded dramatically over the last 40 years. Today nurses must be adequately instructed to perform a total assessment, as well as a focus assessment,

including the use of equipment, formerly the domain of physicians only. The skill of performing a physical assessment must be practiced repeatedly to acquire expertise.

EXAMINATION TECHNIQUES

INSPECTION

Observe the client while facing him or her in the bed or chair. Observe the client's skin color and texture; check for lesions and hair distribution. Look at overall body structure. If the client can be out of bed, observe gait and stance. Note all parts of the body as the examination proceeds. Inspection also evaluates verbal and behavioral responses and mental status.

PALPATION

Obtain information by using the hands and fingers to palpate. A light or deep palpation depends on the area being palpated. The palmar surface of fingers and finger pads are used to determine position of the organs, size and consistency, fluid accumulation, pain, and masses. The ulnar surface of the hand is used to distinguish vibration and temperature. The moisture and warmth of the skin can also be determined during palpation.

PERCUSSION

Produces sound waves by using the fingers as a hammer. Place the interphalangeal joint of the middle finger on the skin surface of the nondominant hand. Using the tip of the middle finger of the dominant hand, strike the placed finger. Vibration is produced by the impact of the fingers striking against underlying tissue. Sound or tone of the vibration is determined by body area or organ percussed. Normal lung areas produce a resonance sound; liver sounds are dull and a flat sound is heard over muscle.

AUSCULTATION

Place the stethoscope on the client's bare skin to listen for the presence and characteristics of sound waves. The bell of the stethoscope is used to detect low-pitched sounds; the diaphragm detects high-pitched sounds. Note variations in intensity, pitch, duration, and quality.

● Inspection.

● Percussion.

● Palpation.

● Auscultation.

FOCUS (SHIFT) ASSESSMENT

A full physical assessment is completed upon admission. A focus assessment, also called a bedside or shift assessment, is performed at the beginning and ending of the shift and concentrates on the vital assessment parameters; tracks changes from shift to shift and should take no more than 5 minutes to complete. Several activities in the assessment can be completed at the same time. Usually, it is individualized to fit the client's condition, diagnosis, and level of acuity.

Step 1.

Step 1

Evaluate the client's level of consciousness, eye contact and responsiveness, color and texture of the skin, any IVs, dressings or tubes visible. Ask appropriate questions to determine orientation to time and place. Establish the nurse–client relationship at this time.

Step 2.

Step 2

Assess vital signs. While taking the client's pulse, feel skin temperature and moisture. Check bilateral radial pulses. Observe for edema in face or neck. Individualize the assessment; for example, with a neurological condition, check pupils.

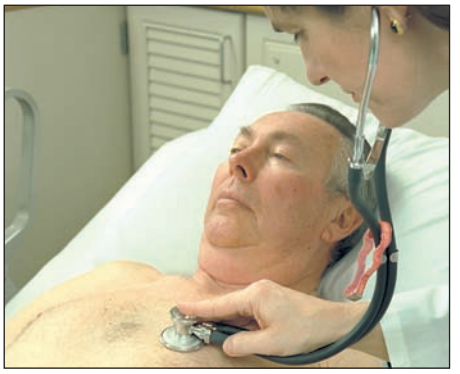

Step 3.

Step 3

Remove client's gown or raise gown. Use stethoscope to listen to heart sounds, apical pulse and breath sounds bilaterally. Observe breathing patterns, symmetry of chest movement, shape of chest, and depth of respirations. Check for skin turgor.

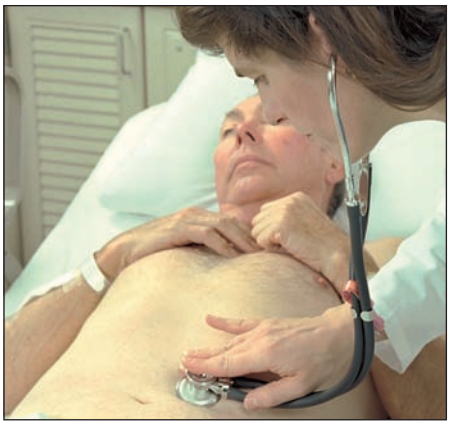

Step 4.

Step 4

Auscultate abdomen for bowel sounds. Use palpation and percussion techniques only if appropriate to diagnosis. Palpate bladder if necessary (based on output). If catheter is in place, observe urinary output for color, odor, consistency, and amount.

Step 5.

Step 5

Assess lower extremities for warmth, color, moisture, presence of pedal or popliteal pulses, muscle tone and sensation. Assess for pedal edema or general edema in the lower extremities. Check traction or casted areas for skin breakdown, alignment and placement.

Step 6.

Step 6

Have client turn onto side or sit at edge of bed. Assess posterior lung fields and symmetry of chest movement with inspiration. Assess skin for pressure areas, particularly coccyx and heels when client returns to side-lying position. Evaluate client's ability to move in bed.

TABLE 11–1 GLASGOW COMA SCALE

A. Motor response.	Points
1. Obeys a simple command	6
2. Localizes painful stimuli; attempts to remove offending stimulus; lack of obedience	5
3. Withdrawn—moves purposelessly in response to pain	4
4. Abnormal flexion—decorticate posturing	3
5. Extensor response—decerebrate posturing	2
6. No motor response to pain	1
B. Verbal response.	**Points**
1. Oriented—to time, place, and person	5
2. Confused conversation; disorientation in *one* or more spheres	4
3. Inappropriate or disorganized use of words (cursing); lack of sustained conversion	3
4. Responds with incomprehensible sounds	2
5. No verbal response (Record T if an endotracheal or tracheostomy tube is in place)	1
C. Eye opening.	**Points**
1. Spontaneous when a person approaches	4
2. In response to speech	3
3. Only in response to pain	2
4. Do not open, even to painful stimuli (Record C if eyes are closed by swelling)	1

Note: This scale is a tool for assessing a client's response to stimuli. Scores range from 3 (deep coma) to 15 (normal). Add numbers to get a total score.

PHYSICAL ASSESSMENT

Neurologic Assessment

The neurologic examination begins with the initial contact with the client. Evaluation of verbal responses, movement, and sensation is carried out throughout the examination. In addition, functions of the cerebrum, cerebellum, cranial nerves, spinal cord, and peripheral nerves are assessed. The level of consciousness is the most sensitive and reliable index of cerebral function.

Assessment	Normal	Abnormal
Level of Consciousness		
Evaluate **verbal responses** If client seems awake and alert but does not respond properly, check to see if client is blind, deaf, or speaks another language	Alert Mood appropriate to situation Responds to verbal command Answers questions appropriately Speaks clearly Oriented to time, person, place, and purpose Recent and remote memory intact	Drowsy Difficult to awaken Unable to give date, month, place Irritable Memory defect Difficulty finding words Does not recognize family Does not respond to own name
Observe and test symmetry of **motor responses** on both sides of body	Eyes open Follows command to stick out tongue, squeeze fingers, move extremities	Eyes closed Does not follow directions to stick out tongue, squeeze fingers, or move extremities

(continued)

PHYSICAL ASSESSMENT (*continued*)

Assessment	Normal	Abnormal
Exert pressure on nailbed with pen Apply pressure to supraorbital ridge Pinch Achilles tendon Test each side independently	Responds to painful stimuli by reaching out or trying to stop pressure	Does not localize or withdraw from painful stimuli or withdraws abnormally Assumes *decorticate posturing* (legs extended; feet extended with plantar flexion; arms internally rotated and flexed on chest): may be due to lesion of corticospinal tract near cerebral hemisphere Assumes *decerebrate posturing* (arms stiffly extended and hands turned outward and flexed; legs extended with plantar flexion): may be due to lesion in diencephalon, pons, or midbrain Assumes *flaccid posturing* (no motor response): may be due to extreme brain injury to motor area of brain
		Involuntary movements *Choreiform* (jerky and quick): present in Sydenham's chorea *Athetoid* (twisting and slow): present in cerebral palsy *Tremors:* hyperthyroidism, cerebellar ataxia, parkinsonism *Spasms:* cord-injured clients *Seizures:* brain injury, heat stroke, electrolyte imbalance *Asterixis:* metabolic encephalopathy due to liver or kidney failure
Pupil Assessment Observe **pupils** using penlight and pupil gauge or an automated pupillometer		
Size of pupils	Diameter: 1.5–6 mm	Unilateral dilation: sign of third cranial nerve involvement Bilateral dilation: sign of upper brain stem damage Unilateral dilation and nonreactive: sign of increased intracranial pressure (ICP) or ipsilateral oculomotor nerve (III) compression from tumor or injury
Shape of pupils	Round and midposition	Midposition and fixed: sign of midbrain involvement Pinpoint and fixed: sign of pontine involvement or opiate effect
Equality of pupils	Equal	Unequal: sign that parasympathetic and sympathetic nervous systems are not in synchronization
Observe **reaction to light** by using penlight in darkened room	Pupil constricts promptly	Sluggish reaction or failure to react to light: early warning of deteriorating condition or elevated ICP

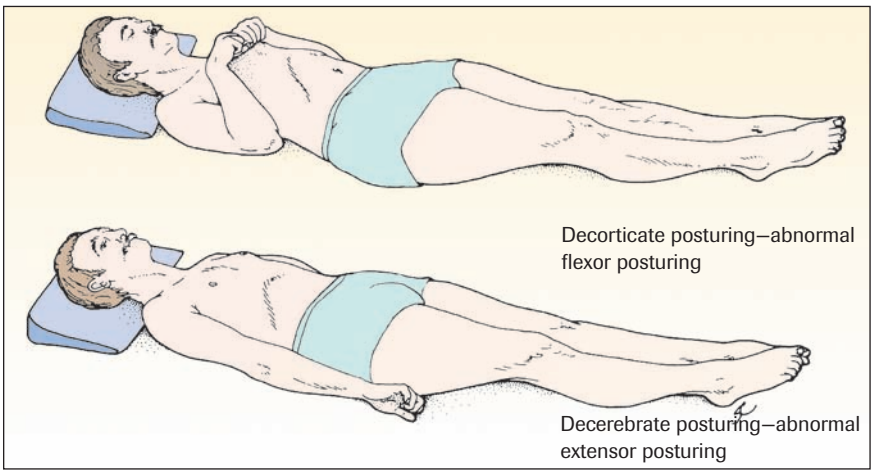

Assessment	Normal	Abnormal
Open eyelid being tested; cover opposite eye		Light reflex is the most important sign differentiating structural (cranial involvement) from metabolic coma due to extracranial cause (e.g., diabetic coma), which does not alter light reflex

● Move light toward client's eye from side position.

Observe consensual **light reflex** Hold both eyelids open Shine light into one eye only Observe opposite eye	Both pupils constrict	Pupil does not constrict: sign that connection between brain stem and pupils is not intact
Check **accommodation** (ability of lens to adjust to objects at varying distances)	Lens can adjust	When the lens thickens (often in the fifth decade of life) accommodation can be limited
Motor Function Assessment		
Assess bilateral **muscle strength** Test hand grip by asking client to squeeze your fingers Rate muscle strength from 0 to 5 with 0 indicating no muscle contraction and 5 (normal) indicating full range of motion against gravity with full resistance	Muscle strength is equal bilaterally	Absent or weak muscle function on one side may be sign of hemiplegia (paralysis of one side of the body); or hemiparesis (weakness on one side); paraplegia (paralysis of the legs or lower part of the body); tetraplegia or quadriplegia (paralysis of arms and legs)
Test arm strength by asking client to close eyes and hold arms out in front with palms up	Maintains position for 20–30 seconds	Cannot maintain position—downdrifts one extremity

● Test client's hand grip.

Assess **flexion** and **extension** strength in extremities Stand in front of client, place your hand in front of client, and ask client to push your hand away	Equal response in both arms	Unequal response in arms Asymmetrical response Inability to perform movements

(continued)

PHYSICAL ASSESSMENT (*continued*)

Assessment	Normal	Abnormal
Place your hand on client's forearm and ask client to pull arm upward		
Position client's leg with knee flexed and foot resting on bed; as you try to extend leg, ask client to keep foot down	Equal response in both legs	Unequal response in legs
Place one hand on client's knee and one hand on client's ankle; ask client to straighten leg as you apply resistant force to knee and ankle		
Assess **muscle tone**	Client resistance is apparent	
Flex and extend client's upper extremities to assess how well client resists your movements		Increased resistance: sign of increased muscle tone from muscle rigidity or spasticity in upper motor neuron (UMN) lesions, such as with CVA and parkinsonism Decreased resistance to leg extension and arm flexion in UMN lesion (CVA)
Flex and extend client's lower extremities to assess resistance		Weakness in lower motor neuron (LMN) and cerebellar lesion
Assess **coordination**	Client able to perform coordinated movements on request: hand, foot, hand and leg positioning	Uncoordinated movements: may be due to cerebellum or basal ganglia involvement
Hand coordination		
Ask client to pat both thighs as rapidly as possible		
Ask client to turn hands over and back in quick succession		
Ask client to touch thumb with each finger in rapid succession—repeat with other hand		Clumsy movement with cerebellar involvement
Foot coordination		
Place your hands close to client's feet		
Ask client to tap your hands alternately with the balls of feet		
Hand positioning coordination		
With client's eyes open, extend your hand in front of client's face		
Ask client to touch nose with index finger several times in rapid succession		Tremor as nose is approached indicates cerebellar involvement
Repeat test with client's eyes closed		Inability to perform task with eyes closed: may be due to loss of positioning sense
Leg positioning coordination		
Ask client to put heel on opposite knee and to slide heel down leg to foot		

Assessment	Normal	Abnormal
Assess **reflexes**		
Blink reflex		
Hold client's eyelid open Approach client's eye unexpectedly from side of head Complete corneal touch	Eyes close immediately	Absence of blink response; eyelid continuously in open position: due to fifth or seventh cranial nerve (pons) involvement; blindness
Gag and swallow reflex		
Open client's mouth and hold tongue down with tongue blade Touch back of pharynx on each side with applicator stick	Gag and swallow reflex present	Absence of gag and swallow reflex; inability to swallow food or liquid: due to ninth or tenth cranial nerve (medulla) involvement
Plantar reflex		
Run top of pen along outer lateral aspect from heel to little toe of client's foot Continue tracing a line across ball of foot toward great toe	Toes are pointed down	Babinski response: great toe dorsiflexes; other toes fan on foot of paralyzed side in CVA, and bilaterally in spinal cord injury (SCI)

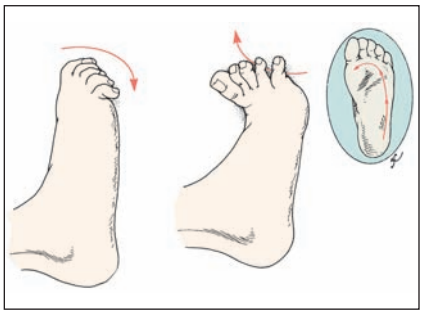

Testing plantar reflex.

Negative Babinski.

Positive Babinski.

Deep tendon reflex		
Ask client to relax Position limb to be assessed so that muscle is somewhat stretched Using reflex hammer, strike tendon quickly	Biceps reflex: flexion at elbow and contracting of biceps muscle Triceps reflex: extension at elbow and contraction of triceps muscle Patellar reflex: extension of knee and contraction of quadriceps	Absent or diminished: sign of cervical cord (C–5 or C–6) involvement Absent or diminished: C–7 or C–8 cord involvement Absent or diminished: L2–3 or L3–4 cord involvement
Assess according to scale		
Grading Scale		
4+ Hyperactive or exaggerated 3+ More brisk than usual but not indicative of disease state		Indicates upper motor neuron (UMN) lesion or SCI
2+ Average or normal 1+ Slightly diminished, low normal 0 No response		Seen with lower motor neuron (LMN) lesion
Sensory Function		
Assess **superficial sensations**		
Pain		
Ask client to close eyes Stroke or touch skin with cotton-tipped applicator, alternating cotton tip with wooden end	Ability to distinguish between sharp and dull sensations	Alterations in pain or temperature sensations: indicate lesion in posterior horn of spinal cord or spinothalamic tract of cord

(continued)

PHYSICAL ASSESSMENT (*continued*)

Assessment	Normal	Abnormal
Ask client to distinguish sharp and dull pain		
Temperature		
Fill two test tubes with water, one hot, one cold		
Ask client to close eyes and touch client's skin with test tubes	Ability to distinguish between hot and cold	
Touch		
Ask client to close eyes Stroke cotton wisp over client's skin	Ability to identify light touch—equal bilaterally	Anesthesia = loss of light touch Analgesia = absence of sense of pain Hypalgesia = decreased pain sensation Hyperalgesia = exaggerated sensitivity to pin prick (pain)
Positioning		
Ask client to close eyes Grasp client's finger with your thumb and index finger Move client's finger up and down Ask client to identify direction finger is moving Repeat with great toe	Ability to identify position or mimic position with other hand	Inability to determine direction of movement: may be due to posterior column or peripheral nerve disease
Vital Signs		
Assess **temperature**		
If client is semiresponsive or nonresponsive, take rectal, axillary, or tympanic temperature If rectal temperature is contraindicated or there are signs of increased ICP, use alternate method.	Ability to maintain normal body temperature (approximately 98.6°F, or 37°C)	Inability to maintain normal temperature: may be due to damage to hypothalamus No sweating below level of injury; due to spinal cord injury Hypothermia
Assess **apical** and **radial pulses** Note character of pulses Count heart rate Count radial pulse rate	Regular rhythm Rate 60–100 BPM Apical and radial rates are equal	Fast heart rate due to decreased blood volume, arrhythmia, heart failure, fever, medulla dysfunction Irregular rhythm with premature beats due to hypoxia, cardiac irritability, or electrolyte imbalance Pulse deficit due to premature beats or ineffectual cardiac contraction.

● Assess client's apical pulse.

Assessment	Normal	Abnormal
Assess **respiration** Assess rate and pattern of breathing	Regular rate: 12–20 breaths per minute	Cheyne–Stokes (rhythmic increase in depth of breathing followed by period of apnea) may be due to deep cerebral or cerebellar lesion or condition altering cerebral perfusion Central neurogenic (sustained) hyperventilation due to upper brain stem involvement Ataxic (Biot's) breathing unpredictably irregular, due to lower brain stem involvement
Monitor arterial blood gases if signs of respiratory imbalances occur	pH: 7.35–7.45 P_{CO_2}: 35–45 mm Hg HCO_3: 22–26 mEq/L	Alterations in pH and P_{CO_2} values indicate respiratory imbalances: pH below 7.35 and P_{CO_2} above 45: sign of respiratory acidosis (hypoventilation) pH above 7.45 and P_{CO_2} below 35: sign of respiratory alkalosis (hyperventilation) HCO_3 above 26 indicates metabolic compensation for chronic respiratory acidosis (hypoventilation)
Assess **blood pressure** Position neurologic clients in low- to semi-Fowler's position	Normal pressure (range <120/<80)	Systolic blood pressure rises with diastolic pressure remaining same (widening pulse pressure): sign of increased intracranial pressure Blood pressure over 140/90 is a sign of stage 1 hypertension Blood pressure below 90/60 is a sign of hypotension

Korotkoff's Sound Phases for Blood Pressure

Phase I: The pressure level at which the first faint, clear tapping sounds are heard. The sounds gradually increase in intensity as the cuff is deflated. This phase coincides with the reappearance of a palpable pulse (systolic sound).

Phase II: That time during cuff deflation when a murmur or swishing sounds are heard.

Phases III: The period during which sounds are crisper and increase in intensity.

Phase IV: That time when a distinct, abrupt, muffling of sound (usually of a soft, blowing quality) is heard (diastolic sound in children or physically active adults).

Phase V: That pressure level when the last sound is heard and after which all sound disappears (second diastolic sound).

Source: American Heart Association, 1996.

Blood Pressure Classification

Blood Pressure	Systolic	Diastolic
Normal	<120	<80
Pre HBP	120 to 139	80 to 89
Stage I HBP	140 to 159	90 to 99
Stage II HBP	160 and higher	100 and higher

Source: National Heart, Lung and Blood Institute, 2003, May.

ASSESSMENT OF THE HEAD AND NECK

The names of the regions of the head are derived from the bones that form the skull. Knowing the names of the bones and regions of the skull can assist in describing the location of the physical findings.

An understanding of the function of each lobe of the brain allows the nurse to be able to identify potential client problems when an injury occurs to that portion of the brain.

The brain comprises three segments: the brain stem, cerebrum, and the cerebellum. There are 12 cranial nerves, which are discussed later in this chapter, and 31 pairs of spinal nerves with dorsal and ventral roots.

The brain stem is divided into four sections: The *diencephalon* comprises the thalamus, which screens and relays sensory impulses to the cortex, and the hypothalamus, which regulates the autonomic nervous system, stress response, sleep, appetite, body temperature, water balance, and emotions. The *midbrain* is responsible for motor coordination and conjugate eye movements. The *pons* controls involuntary respiratory reflexes and contains projection tracts between the spinal cord, medulla, and brain. The *medulla* contains cardiac, respiratory, vomiting, and vasomotor centers. In addition, all afferent and efferent nerve tracts must pass between the spinal cord and brain through the medulla.

The cerebral hemispheres have an outer layer formed by cellular gray matter, called the cerebral cortex. The two cerebral hemispheres are divided into four major lobes. The frontal lobe controls emotions, judgments, motor function, and the motor speech area. The parietal lobe integrates general sensations; interprets pain, touch, and temperature; and governs discrimination. The temporal lobe contains the auditory center and sensory speech center. The occipital lobe controls the visual area. The cerebellum coordinates muscle movement, posture, equilibrium, and muscle tone.

The 12 cranial nerves are summarized in Table 11–2. The 2nd through 12th nerves arise from the brain stem. The cranial nerves are 12 pairs of parasympathetic nerves with their nuclei along the brain stem.

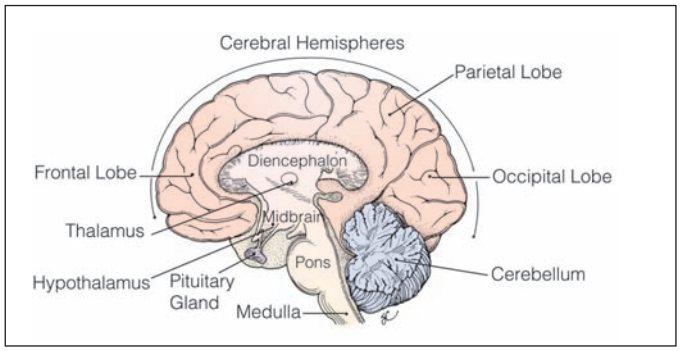

● Lobes of the brain.

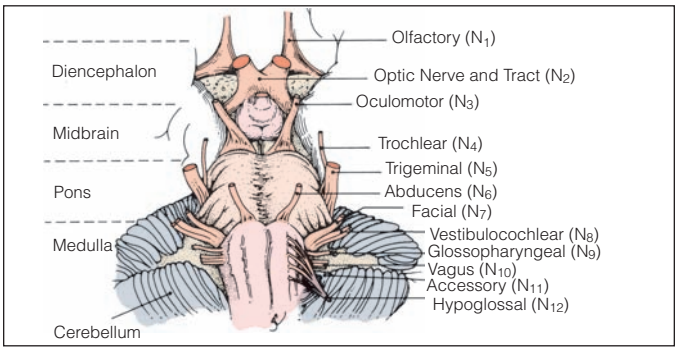

● Brain segments and cranial nerves.

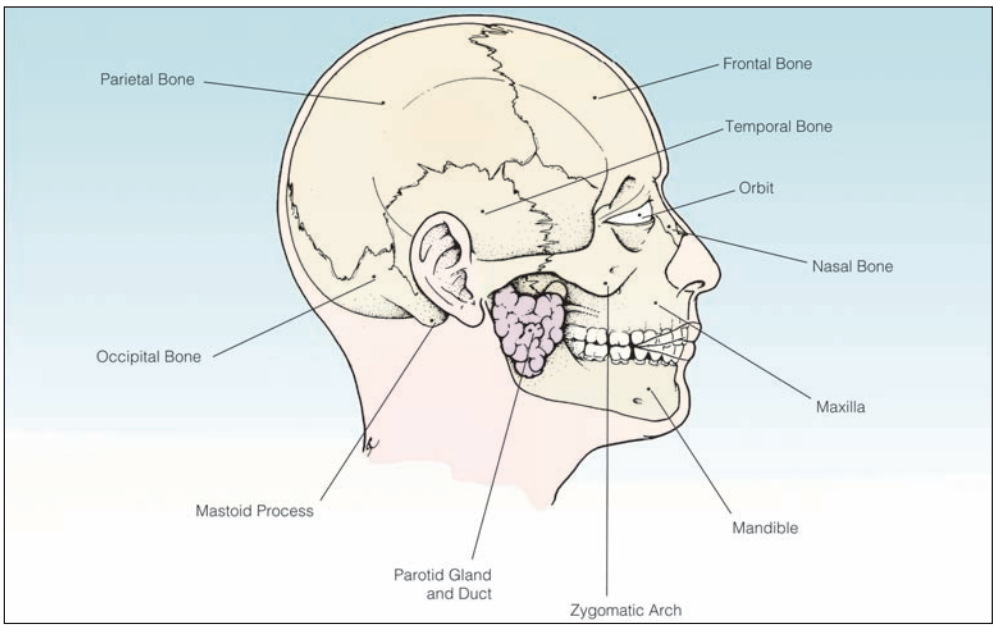

● Bones that form the skull.

TABLE 11–2 CRANIAL NERVES AND THEIR FUNCTION

Cranial Nerve	Function	Testing Cranial Nerves
I Olfactory	Sensory nerve	Recognizes odor in each nostril separately (e.g., coffee)
II Optic	Sensory nerve: conducts sensory information from the retina	Demonstrates visual acuity: can read newsprint
III Oculomotor	Motor nerve: controls four of the six extraocular muscles; raises eyelid and controls the constrictor pupillae and ciliary muscles of the eyeball	Responds to light: pupils constrict; moves eyes medially; elevates upper eyelid
IV Trochlear	Motor nerve: controls the superior oblique eye muscle	Move eyes to the right, up then down, and to the left
V Trigeminal	Mixed nerve with three sensory branches and one motor branch: the ophthalmic branch supplies the corneal reflex	Demonstrates normal facial sensation; clenches teeth with no lateral jaw deviation; blinks as wisp touched to cornea
VI Abducens	Motor nerve: controls the lateral rectus muscle of the eye	Moves eyes laterally
VII Facial	Mixed nerve: anterior tongue receives sensory supply, motor supply to glands of nose, palate lacrimal submaxillary, and sublingual; motor branch supplies hyoid elevators and muscles of expression and closes eyelid	Elevates eyebrows; puffs cheeks; recognizes tastes (sugar, salt)
VIII Acoustic	Sensory nerve with two divisions: hearing and semicircular canals	Hears whisper with each ear separately
IX Glossopharyngeal	Mixed nerve: motor innervates parotid gland; sensory innervates auditory tube and posterior portion of taste buds	Demonstrates gag reflex to tongue blade when touched to back of tongue
X Vagus	Mixed nerve: motor branches to the pharyngeal and laryngeal muscles and to the viscera of the thorax and abdomen; sensory portion supplies the pinna of the ear, thoracic, and abdominal viscera	Same as IX
XI Accessory	Motor nerve: innervates the sternocleidomastoid and trapezius muscles	Shrugs shoulders
XII Hypoglossal	Motor nerve: controls tongue muscles	Sticks tongue out in midline without deviation

HEAD AND NECK ASSESSMENT

Assessment	Normal	Abnormal
Eye Assessment		
Note **visual acuity** by observing client performance of activities of daily living	Adequate performance of activities of daily living	Age-related macular degeneration (AMD) Hyperopia (farsightedness) Myopia (nearsightedness) Cataract (opacification of the lens)
Factors influencing visual acuity include client's previous status and age	Appropriate responses to environment	Enucleation (loss of an eye): may have prosthesis in place
Note exact location, size, and color of any **external lesions**	No external lesions	Circumocular ecchymosis: may be sign of basal skull fracture
Palpate for mobility and firmness		Xanthelasma (small, yellowish, well-circumscribed plaques): may appear on eyelids of clients with

(continued)

HEAD AND NECK ASSESSMENT (*continued*)

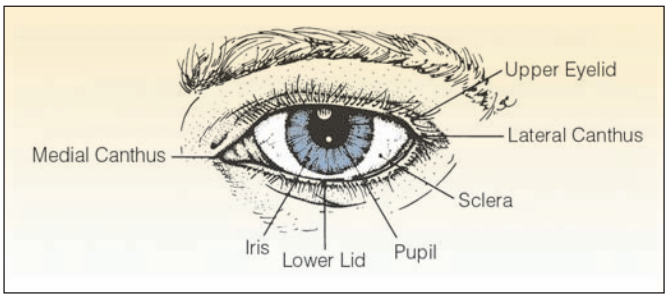

● Anatomy of the eye.

Assessment	Normal	Abnormal
		lipid disorders. *Example:* atherosclerosis
Note **equality of eyelid movement**	Eyelids are equal in movement	Ptosis (paralytic drooping of the upper eyelid)
Note color, consistency, amount, and origin of **discharge** from eyes	No discharge	Sty or hordeolum Thick white discharge; may be due to conjunctivitis
Note **internal lesions**	No internal lesions	Conjunctival or ciliary injection (dilatation of the blood vessels)
Assess differences between **pupil size and reaction**	Both pupils are the same size	Anisocoria (indicates unequal pupil size): may be indicative of neurologic trauma or deficit
Note presence of hemorrhage		Corneal edema (very soft, movable mass that looks like raw egg white): frequently occurs in clients who have increased intracranial pressure Arcus senilis (partial or complete whitish circle near the outer edge of the cornea); usually due to aging; does not affect vision
Observe for opacity of lens—**cataract**	No opacity noted	Cataract present—one or both eyes

● Assess pupil size and reaction.

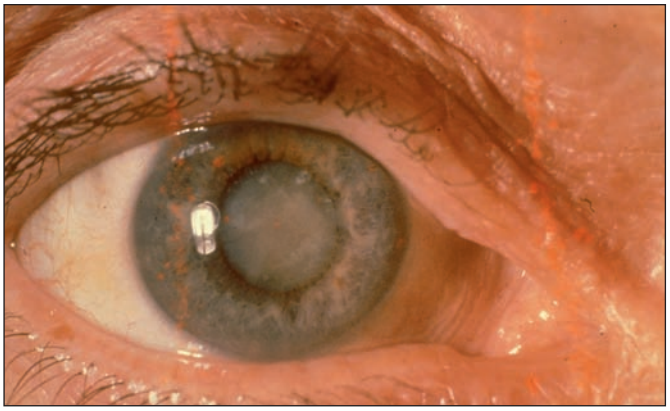

● Cataract: Opacity of the crystalline lens.

Assessment	Normal	Abnormal
Ear Assessment		
Note **auditory acuity** by asking client to indicate if he or she hears normal sounds as you make them	Adequate responses to normal sounds Auditory changes due to aging	Deafness or impaired hearing; excess cerumen in auditory canal Abnormal sounds in the ears (ringing or buzzing) may be caused by ototoxic drugs
Note exact size, color, and location of any **external** lesions Palpate lesions for mobility and firmness	No external lesions	Battle's sign (ecchymosis behind the ear): may be sign of basilar skull fracture
Examine tympanic membrane using an otoscope	Membrance intact, flat, gray with no scarring	White patches show prior infections: yellow or red patches may be infection of middle ear Bulging membrane may indicate increased pressure in middle ear Depressed membrane may indicate vacuum due to blocked eustachian tube.

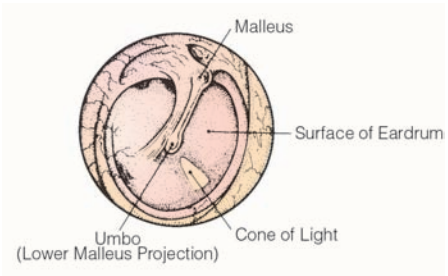

● Anatomy of the tympanic membrane (ear drum).

Note color, quantity, and consistency of any **discharge** from the ears	No discharge Wax buildup	Redness, swelling, and pain may be signs of otitis externa
Test clear fluid for glucose using a Labstix	Glucose test negative	Cerebrospinal fluid leak: may be due to head injury. If drainage is blood and CSF, it will develop a "halo" with a reddish area in the center surrounded by a whitish circle if placed on white material Perforation of tympanic membrane: serosanguineous or purulent drainage Glucose test of clear drainage is positive if CSF

● Two techniques for positioning and inserting an otoscope into ear before viewing.

(continued)

HEAD AND NECK ASSESSMENT (*continued*)

Assessment	Normal	Abnormal
Nose Assessment		
Note any **structural changes** in the nose by observing client breathe Gently occlude one nostril at a time; ask client to breathe through the nonoccluded nostril	Regular breathing with mouth closed Breathing through nonoccluded nostril	Breathing through the mouth only: furuncles may occlude breathing Obstruction in the nose due to deviated nasal septum, swelling of the nasal turbinates, or excessive mucus secretions
Note color, quantity, and consistency of any **discharge** from the nose	Minimal discharge	Cerebrospinal fluid leak (fluid tests positive for glucose with Labstix) Copious, watery-to-thick, mucopurulent discharge: may be due to acute rhinitis Excessive buildup of mucous secretions
Mouth and Lip Assessment		
Note size, color, and location of any **external lesions** Palpate for mobility and firmness	No external lesions	Dehydrated mouth or lips Fissures Pressure sores Necrosis
Note size, color, and location of any **internal lesions** Palpate for mobility and firmness	No internal lesions	Candidiasis (a fungal infection indicated by adherent, white patches)
Neck Assessment		
Note any **lesion or swelling** in the neck Ask client to relax and flex neck slightly Palpate the neck, using the pads of your fingers to move the skin and underlying tissues	Occasional small, mobile, discrete, nontender lymph nodes	Enlarged tender immobile nodes

ASSESSMENT OF THE SKIN AND APPENDAGES

The skin is the body's first line of defense against disease and injury. It is made up of three layers: the epidermis, the dermis, and the subcutaneous tissues.

The epidermis is divided into two avascular, or bloodless, layers: an outer layer that consists of dead keratinized cells and an inner layer that consists of live cells where keratin and melanin are formed. The dermis contains blood vessels, connective tissue, sebaceous glands, and some of the hair follicles. The subcutaneous tissues contain the remainder of the hair follicles, fat, and the sweat glands.

Hair, nails, sweat glands, and sebaceous glands are appendages of the skin. There are two types of sweat glands: eccrine and apocrine. Eccrine glands are distributed over most of the body except for the palms and soles. These glands help control body temperature through their sweat production. The apocrine glands are found mainly in the axillary and genital areas and are stimulated by emotional stress. Bacterial decomposition by aprocrine sweat glands causes adult body odor.

The nail body is made up of dead keratinized cells. Nail production occurs at the nail root. Underlying vessels give the nail its pink color.

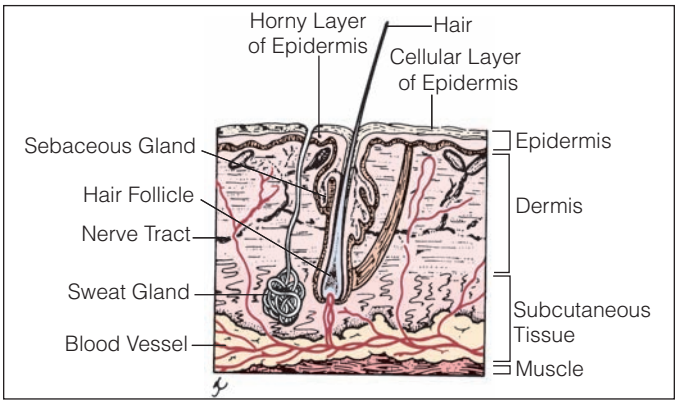

Anatomy of the skin.

SKIN ASSESSMENT

Assessment	Normal	Abnormal
Note **color** of the skin by assessing the oral mucous membranes, the conjunctiva, and the nailbeds	Pink, tan, or brown, depending on the client's basic skin color Oral mucous membrane: moist, pink Conjunctiva: moist, pink Nailbeds: pink	Pallor (decrease in color) *Example*: anemia from acute blood loss (hemorrhage), renal failure, dietary deficiencies, or arterial insufficiency Jaundice (icterus): due to the presence of conjugated or unconjugated bilirubin in the blood and tissues; appears most frequently in the face and sclerae; seen best under natural light *Example*: liver disease Cyanosis (blue, bluegray, or purple discoloration of the skin and mucous membranes): caused by hypoxia, a result of an increased amount of reduced hemoglobin Peripheral: seen in nailbeds and earlobes *Example*: vasoconstriction, venous insufficiency Central: seen in nailbeds, lips (circumoral), and oral mucosa Erythema (redness of the skin): caused by capillary congestion; occurs with inflammation or infection; usually a local finding
Note **pigmentation**	Discolored spots may be due to normal aging	Hyperpigmentation (especially in skin creases) *Example*: use of oral contraceptives, pregnancy, Addison's disease, and hyperthyroidism
Note **turgor** and **mobility**	Smooth and elastic	Tight or stretched and difficult to move: due to local or generalized edema Wrinkled: due to dehydration or caused by rapid weight loss
Pinch skin over the sternum If the fold persists, skin turgor is poor	Resilient and supple	Thin and translucent (parchment) *Example*: chronic steroid use Thin, shiny, and smooth with alopecia on lower extremities *Example*: chronic arterial insufficiency
Assess for **edema** Press finger firmly for 5 seconds into skin on top of foot or inner ankle bone	Resilient and no depression remains after pressure released	Pitting edema: excess interstitial fluid *Example:* congestive heart failure, renal failure, cirrhosis of the liver, venous stasis

● Check quality of the skin.

(continued)

SKIN ASSESSMENT (*continued*)

Assessment	Normal	Abnormal
 Check client for edema.	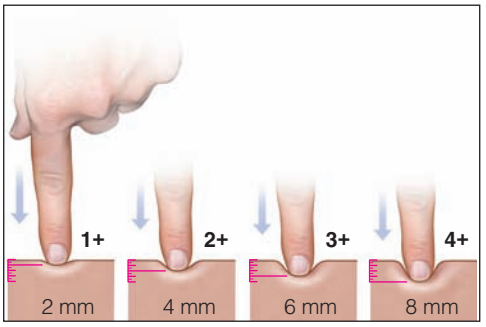 Grading pitting edema.	
Note **moistness** and **temperature** of the skin	Warm and dry	Warm (hot) and moist due to temperature elevation Cool and moist (cold and clammy): may be due to shock states Abnormally dry: may be due to dehydration, decreased sebaceous gland secretions, or the excessive use of soap
Assess for **sensation**—response to external stimuli	Feels touch, sensitive to heat and cold and pressure	Absence of touch or pain sensation *Example*: spinal cord injury or nerve damage Diminished heat and cold sensation *Example*: peripheral vascular disease Itching and tingling *Example:* peripheral vascular disease, peripheral neuropathy, allergy
Note **lesions** on the skin Physical characteristics include color, elevation, shape, mobility, and contents	No lesions present	Macules (flat localized changes in color) *Example*: petechiae, first-degree burns, purpura Papules, plaques, nodules (solid, elevated, varying in size) *Example*: psoriasis, xanthomas Cancerous lesions *Examples:* Basal cell epithelioma— small, smooth papule with atrophic center Melanoma—pigmented tumor; may arise from a blue-black mole Squamous cell—macules with indistinct margins; surface may be crusted Wheals (elevated, circumscribed, transient) *Example:* urticaria, insect bites Vesicles and bullae (clear, fluid-filled pockets between skin layers) *Example:* second-degree burns Pustules (vesicles or bullae filled with purulent exudate) *Example:* furuncles, acne

Assessment	Normal	Abnormal
Nail Assessment		
Note condition of the nails	Smooth transparent layer with white cresent called a lunula	Clubbing occurs with hypoxia or decreased tissue perfusion, cirrhosis, and other conditions Spoon-shaped nails may indicate iron deficiency Thickened nails may relate to circulatory disorder Cracked, split, or broken nails may result from nutrient deficiencies

ASSESSMENT OF THE CHEST: LUNGS, AND HEART

The chest, or thorax area, extends from the base of the neck to the diaphragm. The overall shape of the thorax should be elliptical, although deformities such as barrel chest, pigeon chest, or funnel chest do occur. Total assessment includes the external aspect: the nurse should observe for movement, posture, shape, and symmetry, especially of the breast and axilla area, and the internal components of the lungs and the heart.

The lungs anteriorly extend from 2 to 4 cm above the inner third of the clavicle to the eighth rib at the midaxillary line and the sixth rib at the midclavicular line.

Posteriorly the lungs extend from the third thoracic spinous process and descend to the tenth process or, on deep inspiration, to the twelfth process.

Chest assessment begins with inspection, proceeds to palpation, and then to auscultation. Breath sounds of clients differ due to the depth of breathing, underlying disease, or obesity. Because of these differences, it is difficult to compare the breath sounds of one client with another. The basic principle to remember when auscultating the lungs is to do a comparison between the right and left lung. To make these comparisons, begin auscultating at the apices of one lung, alternating sides as you work down through both lungs. By comparing similar areas in both lungs, you can note changes and determine causes for these changes more easily.

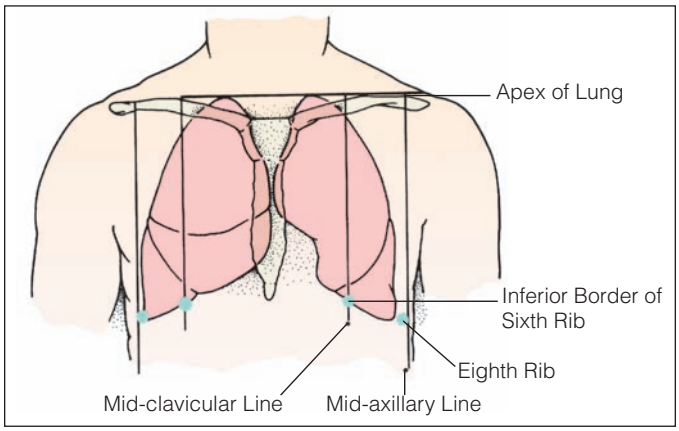

● Anterior anatomical relationship of lungs to skeletal structure.

Examination of the chest usually proceeds from posterior to anterior. For posterior assessment of the lungs, place the client in an upright sitting position with shoulders pulled forward. For anterior assessment, the client can be sitting or supine (especially if female). If the client is lying on his or her side, the lung closest to the bed is mechanically compressed, and true lung sounds cannot be heard.

Ask the client to breathe a little deeper than usual through the mouth. Breathing through the nose produces extra sounds that mask true lung sounds.

The heart is located directly behind the sternum, with the left ventricle projecting into the left chest. The heart is usually thought to be in the left chest for two reasons: the left ventricle produces the most movement (ventricular contraction), and three of the valve sound areas are located to the left of the sternum.

The action of the heart should be assessed both proximally and distally. Proximal assessment involves evaluating heart sounds, heart rate, and rhythm to obtain information about the mechanical activity of the heart. Distal assessment involves evaluating the peripheral pulses to obtain information about the effectiveness of the heart's pumping action.

One method for assessing heart sounds is to start at the aortic area, moving slowly across to the pulmonic area, down to the tricuspid area, and over to the mitral area. This same general progression can also be used in reverse, starting at the mitral area and progressing up to the aortic area. Most clinicians begin

the assessment at the mitral area, which is the point of maximum impulse and where the apical pulse is the loudest.

The most important point to remember in heart assessment is to use the same method every time, repeating the same steps in the same sequence. By using one systematic approach, you learn how to compare the different sounds more easily and not neglect to listen to all areas on the chest.

Breast assessment should include observing for lumps, drainage, dimpling of breast tissue, and presence of asymmetry. The client should also be asked if she has noted any recent changes.

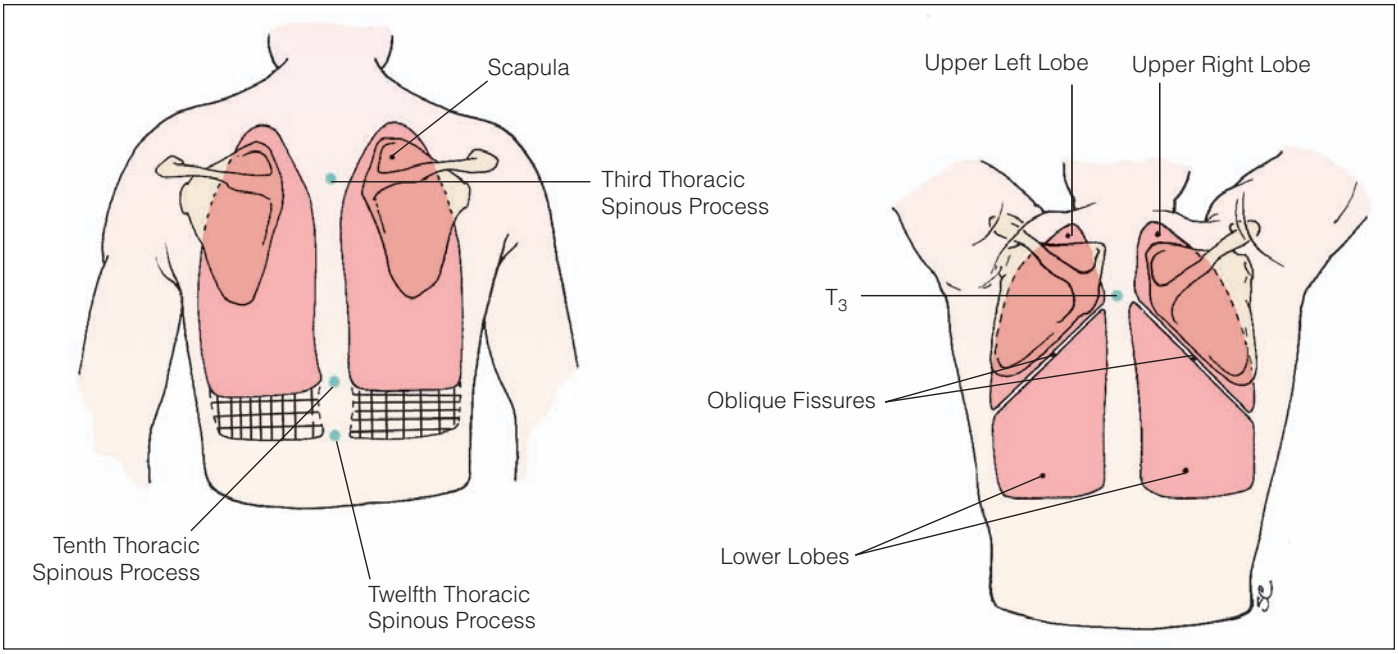

● Posterior relationship of lung lobes to skeletal structures.

CHEST ASSESSMENT

Assessment	Normal	Abnormal
Chest Assessment		
Note respiratory rate—increase may be due to fever, pain, anxiety	A normal or increased rate does not assume a normal tidal volume	Clients may have an increased rate to compensate for decreased tidal volume, but the resultant minute volume is still not sufficient. (Normal minute volume is 6–8 L/minute.) Increased depth: due to neurologic disease, intracranial pressure (ICP) from trauma, drug overdose, exertion, fear, or anxiety Decreased depth: due to neurologic disease, ICP from trauma, drug overdose, respiratory disease, pneumothorax, or pain
Note the **general appearance** of the chest and movement when client breathes	Straight spine, level shoulders Relaxed breathing; rib cage moves symmetrically with respirations	Breathes sitting forward with arms on pillows or overbed table (present with emphysema) Uses accessory muscles (i.e., scalene, trapezius, sternocleidomastoid, pectoralis, or intercostal)

Assessment	Normal	Abnormal
Note **shape of chest**	Anterior–posterior dimension is half of lateral dimension	Anterior–posterior dimension increased in emphysema (barrel chest) Deformities such as scoliosis (lateral curvature), kyphosis (forward curvature), or kyphoscoliosis
Note **position of ribs**	Slant downward	Horizontal is common in COPD Bulging of interspaces during exhalation with retraction on inhalation (present with asthma and emphysema) Chest tilted to one side when client sits or stands: may be due to pain in ribs or chest wall or trauma (i.e., fractured ribs or surgery such as a thoracotomy)
Measure **chest excursion** for range and symmetry: place hands parallel to 10th rib (under scapulae) with thumbs beside spine. Bunch up fold of skin pushing thumbs medially. Ask client to inhale	On inhalation, the thumbs move equidistant away from midline indicating equal expansion	Flail chest: occurs when four or more ribs are broken; area collapses inward during inhalations and outward on exhalation
For anterior assessment, place hands over lower thorax, push medially, then have client inhale. Note equidistant lateral movement of hands	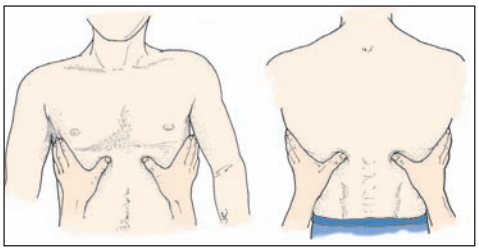 Measure chest excursion while client takes deep breath.	Asymmetrical (unequal) chest expansion occurs with pneumothorax, fractured ribs, atelectasis, or when client's chest splints due to pain
Tactile and Vocal Fremitus Tactile fremitus (vibrations felt on surface of chest as sound passes through tissue) Palpate upper thorax and ask client to say "ninety-nine"; vibrations detected as hands move down thorax	Varied because it depends on thickness of chest wall 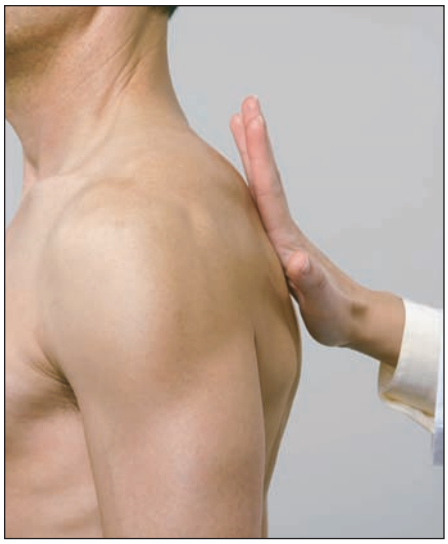 Palpation for tactile fremitus.	Decreased sounds: obesity, emphysema, pneumothorax, and possible asthma Increased sounds: heard when lung is filled with fluid-consolidation (pneumonia) or tumors Absent sounds: atelectasis or pleural effusion Asymmetric sounds: abnormal Normal sounds: found with bronchitis or pulmonary edema

(continued)

CHEST ASSESSMENT (*continued*)

Assessment	Normal	Abnormal
Lung/Respiratory Assessment		
Complete a **general assessment** of the lungs		
Respiratory rate	12–20 respirations/minute	Increased respiratory rate: may be due to increased metabolic needs (fever), mechanical injury, surgery, or trauma to chest wall
Respiratory depth or volume	Normal depth is equal to about 500 mL	
Auscultation: note location and quality of **lung sounds**		
Note presence of *adventitious (extra) sounds,* such as rales/crackles, wheezes, and rhonchi, or pleural friction rub	No extra sounds heard—symmetrical areas should be the same in quality and intensity	*Discontinuous Sounds:* *Crackles* (rales) are due to sudden opening of closed airways, indicating hypoventilation; usually heard as soft, high-pitched scratching sounds, like hair strands rubbing together at end of inspiration Heard in dependent areas of bedridden clients or in early CHF. May be collapsed or fluid-filled alveoli. Simulate by rubbing hair together in front of your ear *Continuous Sounds:* *Wheezes* are produced by air passing through airways narrowed by edema, spasm or mucus; may be heard on inspiration but more often louder on expiration; high-pitched and musical *Rhonchi* are low-pitched rumbling, coarse; sounds heard on inhalation and exhalation. Fluid-blocked airways—may be cleared with coughing. *Sibilant wheezes* are high-pitched, musical sounds; may be caused by asthma, increased secretions, or edema *Pleural friction rub* is produced when inflamed pleurae rub together in the absence of normal pleural fluid; localized, high-pitched, harsh, and scratchy; frequently transient; may be heard on inspiration and expiration *Stridor* is an inspiratory wheeze heard in the neck due to partial obstruction at upper airway—tracheal or laryngeal level

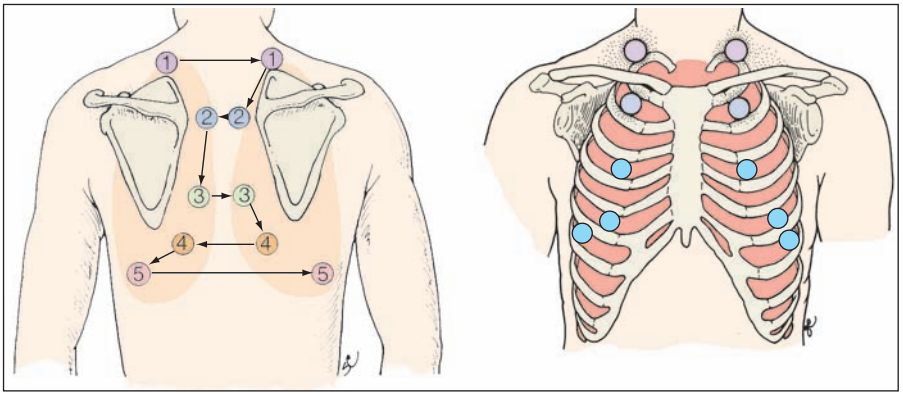

● Stethoscope placement sites for posterior (left) and anterior (right) auscultation of breath sounds. Follow arrows for sequence of examination.

● Listen to posterior breath sounds.

Assessment	Normal	Abnormal
Evaluate *breath sounds*		
Bronchovesicular breath sounds		
Heard over the mainstem bronchi below the clavicles and adjacent to the sternum, between scapulae	Moderate to high pitch, with moderate amplitude Hollow, muffled quality Inspiration and expiration equal in duration	Bronchial or bronchovesicular sounds heard in the perimeter where vesicular sounds are expected indicate consolidation such as pneumonia. The client's spoken and whispered words are also clearly heard by the examiner over consolidated lung areas
Vesicular (normal) breath sounds		
Heard over lung parenchyma (heart will mask breath sounds on the left side)	Low to medium pitch, with low amplitude Soft, whooshing quality	Breath sounds may be absent over areas of atelectasis, pneumothorax, or pleural effusion
Lungs extend anteriorly to the sixth intercostal space	Inspiration two to three times longer than expiration	
Bronchial breath sounds		
Heard over the trachea above the sternal notch	High pitch and amplitude Harsh, loud, tubular quality Expiration longer than inspiration	
Lungs extend posteriorly to T10 on expiration, to T12 on deep inspiration		Breath sounds are decreased (faint) with hypoventilation, early atelectasis, and COPD
Heart Assessment		
Evaluate **atrioventricular heart sounds** (S_1 heart sound). Use diaphragm of stethoscope—best for picking up high-pitched sounds	S_1 (the first heart sound, a combination of the mitral and tricuspid closure) heard best over the mitral and tricuspid areas. S_1 louder than S_2 in this area	Heart sounds not heard in the area prescribed (e.g., with left ventricular hypertrophy, mitral sound moves laterally)
Mitral value sounds		
Heard best at left, fifth intercostal space at, or medial to, the midclavicular line		
Tricuspid valve sounds		
Heard best at fifth intercostal space, left sternal border	S_1 also heard at this area and is louder than S_2	
Evaluate **semilunar heart sounds** (S_2 heart sounds)	S_2 (the second heart sound, a combination of the aortic and pulmonic closure): heard best over the aortic and pulmonic areas	Sounds altered with aortic stenosis (thrill) and hypertension (accentuated sound)

● Auscultate heart sounds.

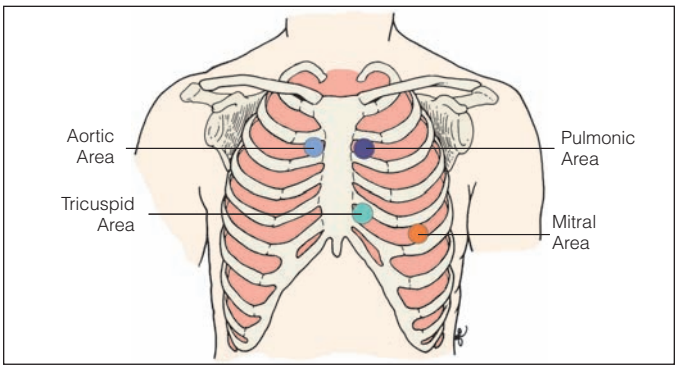

● S_1 heard best over mitral and tricuspid areas. S_2 heard best over aortic and pulmonic areas.

(continued)

CHEST ASSESSMENT (*continued*)

Assessment	Normal	Abnormal
Aortic valve sounds		
Heard best at second intercostal space, right sternal border		
Pulmonic valve sounds	Part of S_2 is louder than S_1 in this area. May be heard separately from aortic closure if client inhales deeply	Accentuated with pulmonary hypertension
Heard best at second intercostal space, left sternal border		
Evaluate presence of **diastolic heart sounds**		
Use bell of stethoscope—best for picking up low-pitched sounds and gallops. Place lightly on chest with client in left side lying position	Quiet and low-pitched	Murmurs originating from stenotic valves
S_3 (ventricular gallop)		
Heard just after S_2, at the apex or at lower, left sternal border	May be a physiologic finding in children and young adults Abnormal finding in older clients	Almost always signifies heart failure in client over age 40
S_4 (atrial gallop)		
Heard just before S_1, at the apex or at lower, left sternal border; occurs when blood flow from atrial contraction meets increased resistance in ventricle	Normal finding in elderly	Heard in older individual with hypertension
Assess for **heart murmurs**, heard between heart sounds	Faint sound More common during systole	Faint or loud enough to be heard without a stethoscope
Produced by atypical flow of blood through the heart (e.g., irregularity or partial obstruction, increased flow in normal area, flow into dilated chamber, flow through abnormal passage); regurgitant flow	Often found in children and young adults	Occurs during systole or diastole(diastolic murmurs are almost always pathologic)—found in older clients with heart disease or infants and children with congenital heart defects
Occurs during systole (between S_1 and S_2) or during diastole (between S_2 and S_1)		
Evaluate the **apical pulse** when assessing for general heart rate and rhythm of contractions	Regular rhythm Heart rate: 60–100 beats/minute	Irregular rhythm (dysrhythmia) may be regularly irregular or irregularly irregular (i.e., atrial fibrillation)
Auscultate at the apex of the heart (left, fifth intercostal space at the midclavicular line)	Moderate bradycardia common in well-trained athletes	Bradycardia (less than 60 beats/minute)
Palpate and view pulse on chest wall if client's chest wall is thin enough	Mild tachycardia possible with stress, infection, or fever	Tachycardia (more than 100 beats/minute)
Assess for **irregular apical pulse**		
With another nurse, take apical and radial pulses *simultaneously*		
Compare beats per minute for both pulses	Equal apical and radial pulses = no pulse deficit	Fewer beats at the radial area may indicate an irregular apical pulse, producing ineffective pumping

Assessment	Normal	Abnormal
Auscultate apical pulse and compare to carotid pulse	Two pulses are synchronous	Apical pulse greater than carotid pulse indicates a pulse deficit

Compare apical and carotid pulse to identify pulse deficit.

Palpate **peripheral pulses*:** radial, brachial, femoral, popliteal, dorsalis pedis, posterior tibial (For special cases, after carotid surgery, palpate temporal pulse also)	Easily palpated Equally strong on both sides Posterior tibial pulse usually weaker than femoral	Difficult to palpate Unequal pulses Weak pulse Absent pulses
Guidelines for palpating peripheral pulses:		
If pulse is not immediately palpable, examine adjacent area—pulse locations differ with clients		
Palpate weak pulses gently so that you do not obliterate pulse with too much pressure		
If you cannot differentiate your pulse from client's pulse, check your radial or carotid pulse, or observe monitor pattern		
When peripheral pulses cannot be palpated, use a Doppler ultrasound stethoscope and grade according to scale		

Palpate peripheral pulse, dorsalis pedis.

**See* assessing peripheral pulses in Chapter 10, Vital Signs

ASSESSMENT OF THE ABDOMEN, SPLEEN, KIDNEY, LIVER AND GENITOURINARY TRACT

The abdomen extends from the diaphragm to the pelvis. Generally speaking, there are two body systems present in this area: the gastrointestinal system and the genitourinary system.

The gastrointestinal system begins at the mouth and consists of the esophagus, stomach, the small and large intestines, and associated organs that include the liver, pancreas, and spleen.

The urinary tract consists of the kidneys, ureters, bladder, and the urethra. The urinary tract should be assessed frequently and accurately because changes in urine production reflect changes in other body systems.

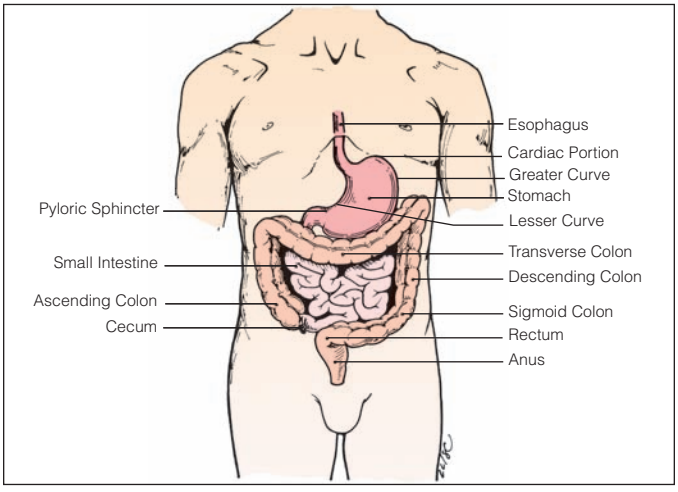

Assessment requires knowledge of abdominal organ anatomy.

The most common way to assess the urinary tract is to note the quantity and quality of the urinary output. Some medications or foods produce unusual odors and colors in urine (e.g., sulfasalazine [Azulfidine] turns urine a yellow-orange color; asparagus gives urine a musty odor).

External male genitalia include the penis, the scrotum, and the testicles. External female genitalia include the vulva, the urethral orifice, and the vagina.

ASSESSMENT OF THE ABDOMEN, LIVER, SPLEEN, KIDNEY, AND GENITOURINARY TRACT

Assessment	Normal	Abnormal
Abdomen		
Have client lie flat in bed		
At the client's abdominal level, inspect the **general contour** of the abdomen	Abdomen flat from chest to pubis with concave indentation at umbilicus	Scaphoid (concave) abdominal contour: due to inadequate nutritional intake to meet caloric need or inadequate food absorption
		Distended abdomen: caused by gas and fluid accumulation due to lack of peristalsis, hemorrhage, or intestinal leakage after trauma (e.g., auto accident or surgery), or ascitic fluid (e.g., liver or cardiac failure)
Inspect for bruising around umbilicus and over planks	No change of skin color around umbilicus or flanks	Acute abdomen
Observe for scars, stretch marks, dilated veins, presence of hernia	Correlate with health history	Dilated veins caused by liver disease
		Bulge seen with defect in abdominal wall
Assess **circumference** for intraabdominal hemorrhage or ascites by placing a tape measure around the largest circumference of the abdomen and drawing two lines around client's entire abdomen, one line at the top of the tape measure, one line at the bottom of the tape measure; perform measurement when client exhales	No increase in abdominal circumference	Abdominal circumference increases steadily within 1–2 hours
Auscultate abdomen to assess presence and quality of **bowel sounds**		
Place diaphragm of stethoscope firmly on right lower quadrant and count sounds for 1 minute	Bowel sounds gurgle, about 5–30 per minute	Hyperactive bowel sounds: due to blood in GI tract, diarrhea, or to partial bowel obstruction (sounds become high-pitched and tinkling or come in "rushes," followed by silence as obstruction progresses)
Listen at all quadrants, near the center, for several minutes if sounds not heard initially	Varying frequency of sounds with clients and time of day (i.e., more sounds right before and after eating)	
	Decreased or absent bowel sounds after surgery	Bowel sounds hypoactive, quiet, and infrequent: may be due to peritonitis, paralytic ileus, or no obvious cause
	After general anesthesia, normal sounds in 1–2 days	
	After abdominal surgery, normal sounds in 3–5 days	Absent bowel sounds: may be due to complete bowel obstruction or systemic illness

Note: Following abdominal surgery, the return of GI function is determined by the (1) return of flatus, (2) bowel movement, (3) hunger, (4) no nausea or tolerance of oral feeding, (5) flat abdomen/nondistension, rather than the return of bowel sounds. (See Evidence-based rationale, p. 661.)

Assessment	Normal	Abnormal
Palpate abdomen to determine condition of **abdominal muscles** and organs beneath muscles		
Assist client to relax, lie flat in bed, and flex knees. Have client mouth-breathe		

Palpate client's abdomen.

Place your hand flat on client's abdomen, holding your four fingers together and depressing ½ inch	Soft, pliant musculature when relaxed	Rigid, tender muscles/pain produced with cough: may be due to presence of muscle spasm, inflammation or infection (peritonitis)
Have client cough to determine any areas of abdominal tenderness	Cough does not produce pain in abdomen	
Begin palpation at the pubis, moving upward. Palpate any problem areas last to minimize effects of discomfort	No bulges felt No masses felt	Pain or tenderness with quick release of pressure indicates rebound tenderness suggesting peritoneal inflammation
Palpate all quadrants of abdomen to assess organs contained in each quadrant		If hernia is suspected, have client raise head and shoulders and observe for abdominal bulge
Superficial palpation: use slight pressure only with your fingers extended		
Deep palpation: indent the abdominal wall 4–5 cm—may use one hand over the other to apply pressure	No masses felt	Masses felt with colon disease, vascular aneurysm, dilated bowel, distended bladder, or cancer
Liver		
Palpate **liver** by placing left hand behind 11th and 12th ribs with right hand on right abdomen lateral to rectus muscle	Normal liver (difficult to palpate) may feel like sharp ridge with smooth surface	Tenderness may be due to inflammation (hepatitis) Enlarged liver with nontender edge may be due to cirrhosis

Palpation of the liver.

(continued)

ASSESSMENT OF THE ABDOMEN, LIVER, SPLEEN, KIDNEY, AND GENITOURINARY TRACT (*continued*)

Assessment	Normal	Abnormal
Spleen		
Standing on client's right side, palpate spleen. Place left hand under rib cage on left side and elevate rib cage. Press fingers of right hand into left costal margin area and ask client to take a deep breath. You should feel spleen move forward toward right hand	A normal spleen is usually not palpable	Enlarged spleen (which can be palpated) occurs in acute infections such as mononucleosis
Urinary Tract Assessment		
Assess the **external urethra**	Orifice is pink and moist; clear, minimal discharge	Burning or pain at urethral orifice: may indicate urinary infection
Assess the quantity, color, odor, specific gravity, and pH of **urine output**	Output: average 1200–1500 mL/24 hours, or 30–50 mL/hour—should equal oral and IV intake	Increased output: may indicate increased intake, diuresis, potential diabetes mellitus, or inappropriate antidiuretic hormone (ADH) response (e.g., diabetes insipidus) Frequent small amounts of urine output indicate urinary retention or urinary tract infection Decreased output: may indicate dehydration, acute nephritis, cardiac disease, renal failure, or excess ADH response (e.g., head injury)
	Clear, yellow-amber color (vegetarians may have slightly cloudy urine)	Cloudy *(turbid)*: may indicate possible urinary tract infection Dark amber: may indicate very concentrated urine due to dehydration Dark amber to green: may indicate hepatitis or obstructive jaundice
	Slight odor (ammonia-like odor indicates that specimen has been sitting for some time)	Foul-smelling: may indicate urinary tract infection, drug or specific food ingestion (e.g., asparagus) Sweet odor: may indicate acetone from ketoacidosis (i.e., diabetes mellitus)
	Specific gravity: 1.003–1.030	Specific gravity of more than 1.030: indicates dehydration Constant specific gravity of 1.010, regardless of fluid intake: indicates renal failure
	pH range from 4.5–7.5; average is 6–7	Acidic pH—when below 6.0 may indicate starvation or acidosis

● Palpation of the spleen.

Assessment	Normal	Abnormal
		Alkaline pH greater than 7.0: indicates metabolic alkalosis or alkaline ash diet (e.g., vegetarian)
Assess for **blood** in urine using Hemastix or Labstix	No blood present	Smokey to mildly pink-tinged to grossly red-colored urine: indicates blood in urine
Palpate for **bladder distention**	Not normally palpated	Distended bladder (firm, round mass) accompanied by discomfort and urge to void: indicates urine retention (common following surgery, where catheter is not used)
Kidney Assessment		
Assess (palpate) for kidney pain on either side of vertebrae column between last thoracic and 3rd lumbar vertebrae Use indirect percussion to further assess the kidneys	When palpated, client feels no pain	Severe pain, discomfort, or tenderness in the flank region (below rib cage posteriorly and lateral to spine): indicates kidney infection, stones, or kidney disease. Kidney enlargement may indicate neoplasm or polycystic disease
Genital Assessment		
Visually examine the **male genitalia**	Clean No odor	
Retract the foreskin of the uncircumcised penis to note cleanliness, any **lesions**, and **discharge**	No lesions	Unclean Odor Lesions and discharge may indicate venereal disease or cancer
Lift scrotum to inspect for rash	No discharge Size of penis and scrotum vary	Oval and round, dark erosion: may indicate syphilitic chancre
Noting groin area, ask client to strain down	Urethra opens midline of the tip of the glans No bulges in groin area	Hypospadias: due to congenital displacement of the urethral meatus Bulge on straining seen with hernias Indurated nodule or ulcer: may indicate carcinoma
Using thumb and first two fingers, gently palpate each testicle for size, shape, and consistency	Two testicles in the scrotum No nodules felt, no swelling or tenderness	Mass in scrotum: indicates possible hernia, hydrocele, testicular tumor, or cyst Pain indicates inflammatory disease
Visually examine **female genitalia**	Clean No odor	Unclean Odor (musty with bacterial infection)
Assess for signs of sexual abuse	No signs	Bruises, welts, burns, unusual swelling

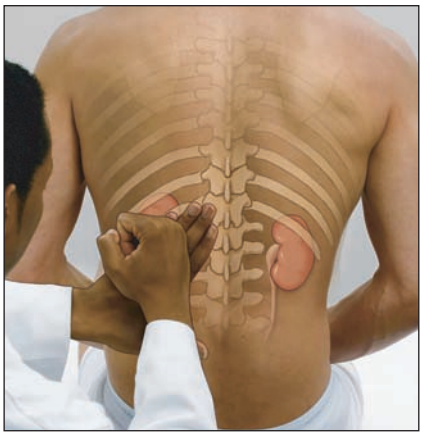

Use of indirect percussion will identify pain.

(continued)

ASSESSMENT OF THE ABDOMEN, LIVER, SPLEEN, KIDNEY, AND GENITOURINARY TRACT (*continued*)

Assessment	Normal	Abnormal
Assess for **lesions** or **discharge** or complaints of itching	Minimal, clear discharge Menstrual flow Lochia (normal discharge after delivery) No lesions No pruritus	Thick; thin, white, yellowish, or green discharge: may indicate trichomoniasis Thick, white, and curdy discharge with pruritus may indicate candidiasis Lesions: could indicate syphilitic chancre, herpes infection, venereal wart, or carcinoma of vulva
Breast Assessment		
Inspect **size, symmetry**, and **contour** of breasts, comparing one side with the other Place client in sitting position Have client remove clothing from waist up Have client raise arms over her head	Size varies with each client Breasts should be fairly equal in size and contour and symmetric in position	Masses, skin thickening, dimpling, or flattened areas: indicate possible cancer
Color, edema, and **venous pattern of skin**	Normal skin color with darker area surrounding nipples No edema or prominent vessels	Erythema: indicates infection or inflammatory carcinoma Edema or increased venous prominence: indicates carcinoma
Inspect **size and shape of nipples** Note direction in which they point, and any **rashes** or **discharge** To palpate breasts, position client supine or on side Place a pillow under the shoulder of the side being examined Using three fingers in a circular motion, compress breast tissue gently against chest wall Systematically examine entire breast, top to bottom, moving medially to laterally into the axilla	Simple inversion of nipples is common Soft, elastic tissue with mobile nodules 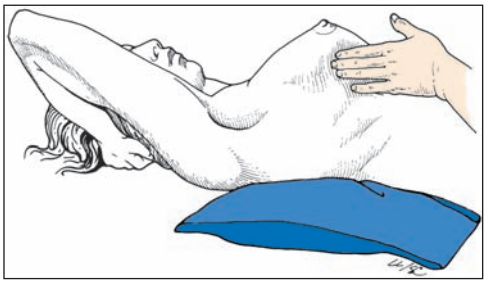 ● Examine breast tissue in circular movement.	Flattening, nipple retraction, or axis deviation of nipple points: may be due to fibrosis associated with cancer Ulcerations of nipples and areola: may be due to Paget's disease Discharge: may not be malignant but should be observed closely Mobile nodules may indicate cystic disease Hard nodules fixed to skin or underlying tissue may indicate cancer When nodules are present Describe location and quadrant of breast where found Note size in centimeters Describe consistency and shape Note tenderness and mobility of nodule in relationship to underlying tissue
Palpate nipples Compress nipple and areola between thumb and index finger to inspect for discharge	No discharge or small amount of milky discharge in previously nursing mother	Bloody discharge: may indicate papilloma
Note **elasticity**	Elastic, no retraction of nipple	Loss of elasticity: indicates possible cancer
Observe for erection of nipple with palpation		Inversion, flattening, or retraction: may indicate cancer

Assessment	Normal	Abnormal
Testicular Examination		
Inspect pubic hair, penis and urinary meatus	No lesions, discharge or itching	Lesions may indicate cancer, discharge, infection; itching, small spots, pubic lice
Palpate scrotum, testes, and observe shape and contour. Observe for swelling, redness, and distended veins or lesions	Should be pear-shaped with left side lower than right; no masses; testes non-tender, smooth and solid	Swelling may indicate orchitis or scrotal edema; scrotal hernia or testicular torsion; varicocele
Inguinal area	Flat, no evidence of masses	Mass may be related to inguinal hernia or cancer

MENTAL HEALTH ASSESSMENT

The mental assessment is completed throughout the physical assessment during the history taking. It is not generally considered a separate entity. Mood, memory, orientation, and thought processes can be evaluated while obtaining the health history. Nutritional preferences and restrictions can be determined as a part of a client care plan and may or may not be included in the general client assessment.

A spiritual assessment can be obtained as a part of the health history, although specific sociocultural beliefs may need to be ascertained separately. The purpose of a spiritual assessment is to facilitate the client adapting to the hospital environment and to help the staff understand stressors the client may be experiencing as a result of belief systems.*

The purpose of a mental status assessment is to evaluate the present state of psychologic functioning and to monitor safety needs of the client. It is not designed to make a diagnosis; rather it should yield data that contribute to the total picture of the client as he or she is functioning at the time the assessment is made.

The specific rationale for completing a mental status assessment is:

- To collect baseline data to aid in establishing the cause, diagnosis, and prognosis
- To evaluate the present state of psychologic functioning
- To evaluate changes in the individual's emotional, intellectual, motor, and perceptual responses
- To determine the client's ability to cope with the present situation
- To assess the need and availability of support systems
- To ascertain if some seemingly psychopathologic response is, in fact, a disorder of a sensory organ (i.e., a deaf person appearing hostile, depressed, or suspicious)
- To determine the guidelines of the treatment plan
- To document altered mental status for legal records

The initial factors that the nurse must consider in completing a mental status assessment are to correctly identify the client, the reason for admission, record of previous mental illness, present complaint, any personal history that is relevant (living arrangements, role in family, interactional experience, history of alcoholism, domestic violence), family history if appropriate, significant others and available support systems, assets, and interests.

The actual assessment process begins with an initial evaluation of the appropriateness of the client's behavior and orientation to reality. The assessment continues by noting any abnormal behavior and ascertaining the client's chief verbalized complaint. Finally, the evaluation determines if the client is in contact with reality enough to answer particular questions that further assess the client's condition.

*Note: For more information on a spiritual–religious assessment, see Chapter 4.

MENTAL STATUS

Assessment	Normal	Abnormal
General Appearance, Manner, and Attitude		
Assess **physical appearance**	General body characteristics, energy level	Inappropriate physical appearance, high or low extremes of energy

(continued)

MENTAL STATUS (*continued*)

Assessment	Normal	Abnormal
Note **grooming**, mode of dress, and **personal hygiene**	Grooming and dress appropriate to situation, client's age, and social circumstance Clean	Poor grooming Inappropriate or bizarre dress or combination of clothes Unclean
Note **posture**	Upright, straight, and appropriate	Slumped, tipped, or stooped
Note speed, pressure, pace, quantity, volume, and diction of **speech**	Moderated speed, volume, and quantity Appropriate diction	Tremors Accelerated or retarded speech and high quantity Poor or inappropriate diction
Note relevance, content, and organization of **responses**	Questions answered directly, accurately, and with relevance	Inappropriate responses, unorganized pattern of speech Tangential, circumstantial, or out-of-context replies
Expressive Aspects of Behavior		
Note **general motor activity**	Calm, ordered movement appropriate to situation	Overactive (e.g., restless, agitated, impulsive) Underactive (e.g., slow to initiate or execute actions)
Assess **purposeful movements and gestures** Assess style of **gait**	Reasonably responsive with purposeful movements, appropriate gestures	Repetitious activities (e.g., rituals or compulsions) Command automation Parkinsonian movements Ataxic, shuffling, off-balance gait
Consciousness		
Assess **level of consciousness**	Alert, attentive, and responsive Knowledgeable about time, place, and person	Disordered attention; distracted, cloudy consciousness Delirious Stuporous
Thought Processes and Perception		
Assess **coherency, logic**, and **relevance** of thought processes by asking questions about personal history (e.g., "Where were you born?" "What kind of work do you do?")	Clear, understandable responses to questions Attentiveness	Disoriented in time, place, person Disordered thought forms Autistic or dereistic (absorbed with self and withdrawn); abstract (absent-mindedness); concrete thinking (dogmatic, preaching)
Assess **reality orientation**: time, place, and person awareness	Orderly progression of thoughts based in reality Awareness of time, place, and person	Disorders of progression of thought; looseness, circumstantial, incoherent, irrelevant conversation, blocking Delusions of grandeur or persecution: neologisms, use of words whose meaning is known only to the client Echolalia (automatic repeating of questions) No awareness of day, time, place, or person

Assessment	Normal	Abnormal
Assess **perceptions** and reactions to personal experiences by asking questions, such as "How do you see yourself now that you are in the hospital?" "What do you think about when you're in a situation like this?"	Thoughtful, clear responses expressed with understanding of self	Altered, narrowed, or expanded perception illusions Depersonalization
Thought Content and Mental Trend		
Assess degree of anxiety Ask questions to determine general themes that identify **degree of anxiety** (e.g., "How are you feeling right now?" "What kinds of things make you afraid?")	Mild or 1+ level of anxiety in which individual is alert, motivated, and attentive	Moderate to severe (2+ to 4+) levels of anxiety
Assess **ideation** and **concentration**	Ideas based in reality Able to concentrate	Ideas of reference Hypochondria (abnormal concerns about health) Obsessional Phobias (irrational fears) Poor or shortened concentration
Mood or Affect		
Assess prevailing or **variability in mood** by observing behavior and asking questions, such as "How are you feeling right now?" Check for presence of abnormal **euphoria**	Appropriate, even mood without wide variations high to low	Cyclothymic mood swings; euphoria, elation, ecstasy, depressed, withdrawn
If you suspect **depression**, continue questioning to determine depth and significance of mood (e.g., "How badly do you feel?" "Have you ever thought of suicide?")	May be sad or grieving but mood does not persist indefinitely	Flat or dampened responses Inappropriate responses Ambivalence
Memory		
Assess **past and present memory** and **retention** (ability to listen and respond with understanding or knowledge); ask client to repeat a phrase (e.g., an address)	Alert, accurate responses Able to complete digit span Past and present memory appropriate	Hyperamnesia (excessive loss of memory); amnesia; paramnesia (belief in events that never occurred) Preoccupied Unable to follow directions
Assess **recall** (recent and remote) by asking questions, such as "When is your birthday?" "What year were you born?" "How old are you?" "Who is the president of the United States now?"	Good recall of immediate and past events	Poor recall of immediate or past events

(continued)

MENTAL STATUS (*continued*)

Assessment	Normal	Abnormal
Judgment		
Assess **judgment, decision-making ability**, and **interpretations** by asking questions, such as "What should you do if you hear a siren while you're driving?" "If you lost a library book, what would you do?"	Ability to make accurate decisions Realistic interpretation of events	Poor judgment, poor decision-making ability, poor choice Inappropriate interpretation of events or situations
Awareness		
Assess **insight**, the ability to understand the inner nature of events or problems, by asking questions, such as "If you saw someone dressed in a fur coat on a hot day, what would you think?"	Thoughtful responses indicating an understanding of the inner nature of an event or problem	Lack of insight or understanding of problems or situations Distorted view of situation
Intelligence		
Assess **intelligence** by asking client to define or use words in sentences (e.g., recede, join, plural)	Correct responses to majority of questions	Incorrect responses to majority of questions indicate possible severe psychiatric disorders
Assess **fund of information** by asking questions, such as "Who is president of the United States?" "Who was the president before him?" "When is Memorial Day?" "What is a thermometer?" (Consider client's cultural and educational background and his or her grasp of English)	Correct responses to majority of questions	Deteriorated or impaired cognitive processes
Sensory Ability		
Assess the **five senses** (i.e., vision, hearing, taste, feeling, and smell)	Able to perceive, hear, feel, touch appropriate to stimulus	Lack of response Suspicious, hostile, depressed Kinesthetic imbalance
Developmental Level		
Assess **developmental level** compared with normal	Behavior and thought processes appropriate to age level	Wide span between chronologic and developmental age Mentally retarded
Lifestyle Patterns		
Identify **addictive patterns** and effect on individual's overall health	Normal amount of alcohol ingested Smoking habits, number of years Prescriptive medications Adequate food intake for physical characteristics	High quantity of alcohol taken frequently Heavy smoker Addicted to illegal drugs Habituative medication; user of over-the-counter or legal medications Anorexic eating patterns Obese or overindulgence of food
Coping Devices		
Identify **defense-coping mechanisms** and their effect on individual	Conscious coping mechanisms used appropriately, such as compensation, fantasy, rationalization, suppression, sublimation, or displacement Mechanisms effective, appropriate, and useful	Unconscious mechanisms used frequently, such as repression, regression, projection, reaction formation, insulation, or denial Mechanisms inappropriate, ineffective, and not useful

OBSTETRICAL ASSESSMENT

Assessment	Normal	Abnormal
Baseline Data		
Assess **breasts** and **nipples**		
Contour and size		
Presence of lumps	No lumps	Lumps
Secretions	Colostrum secretions in late first trimester or early second trimester	Secretions, other than colostrum
Assess **abdomen**		
Contour and size		
Changes in skin color	*Linea nigra* (black line of pregnancy along midline of abdomen) Primiparas: coincidentally with growth of fundus Multiparas: after 13–15 weeks' gestation	
Striae (reddish-purple lines)	On breasts, hips, and thighs during pregnancy After pregnancy, faint silvery-gray	
Scar, rashes, or other skin disturbances	Usually none present	
Fundal height in centimeters (fingerbreadths less accurate): measure from symphysis pubis to top of fundus	Fundus palpable just above symphysis at 8–10 weeks Halfway between symphysis and umbilicus at 16 weeks Umbilicus at 20–22 weeks	Large measurements: EDC is incorrect; tumor; ascites; multiple pregnancy; polyhydramnios, hydatidiform mole Less than normal enlargement: fetal abnormality, oligohydramnios, placental dysmaturity, missed abortion, fetal death
Perineum: assess for scars, lesions, or discharge	None present	Rash, warts, discharge
Evaluate **weight**		
Take **vital signs, blood pressure** (BP), **temperature, pulse,** and **respiration**(TPR)		
Evaluate **lab findings**		
Urine: sugar, protein, albumin	Negative for sugar, protein, and albumin throughout pregnancy	Positive for sugar, protein, and/or albumin
Hematocrit (HCT)	38%–47%	
Hemoglobin (Hgb)	12–16 gm/dL	
Blood type and Rh factor		If Rh negative, father's blood should be typed If Rh positive, titers should be followed; possible RhoGAM at termination of pregnancy
Pap smear		
VD smears and screening		
Antepartum Assessment		
Evaluate **weight** to assess maternal health and nutritional status and growth of fetus	Minimum weight gain during pregnancy: 24 lbs Underweight: 28–42 lbs Obese: 15 lbs or more Normal weight gain: 25–35 to 40 lbs	Inadequate weight gain; possible maternal malnutrition Excessive weight gain: if sudden at onset, may indicate preeclampsia; if gradual and continual may indicate overeating

(continued)

OBSTETRICAL ASSESSMENT (*continued*)

Assessment	Normal	Abnormal
Evaluate **blood pressure**	Fairly constant with baseline data throughout pregnancy	Increased: possible anxiety (client should rest 20 to 30 minutes before you take BP again) Rise of 30/15 above baseline data: sign of preeclampsia Decreased: sign of supine hypotensive syndrome. If lying on back, turn client on left side and take BP again
Evaluate **fundal height**	Drop around 38th week: sign of fetus engaging in birth canal Primipara: sudden drop Multipara: slower, sometimes not until onset of labor	Large fundal growth: may indicate wrong dates, multiple pregnancy, hydatidiform mole, polyhydramnios, tumors Small fundal growth: may indicate fetal demise, fetal anomaly, retarded fetal growth, abnormal presentation or lie, decreased amniotic fluid
Determine **fetal position,** using **Leopold's maneuvers.** Complete external palpations of the abdomen to determine fetal position, lie, presentation, and engagement		
First maneuver: to determine part of fetus presenting into pelvis	Vertex presentation	Breech presentation or transverse lie
Second maneuver: to locate the back, arms, and legs: fetal heart heard best over fetal back		
Third maneuver: to determine part of fetus in fundus		
Fourth maneuver: to determine degree of cephalic flexion and engagement		

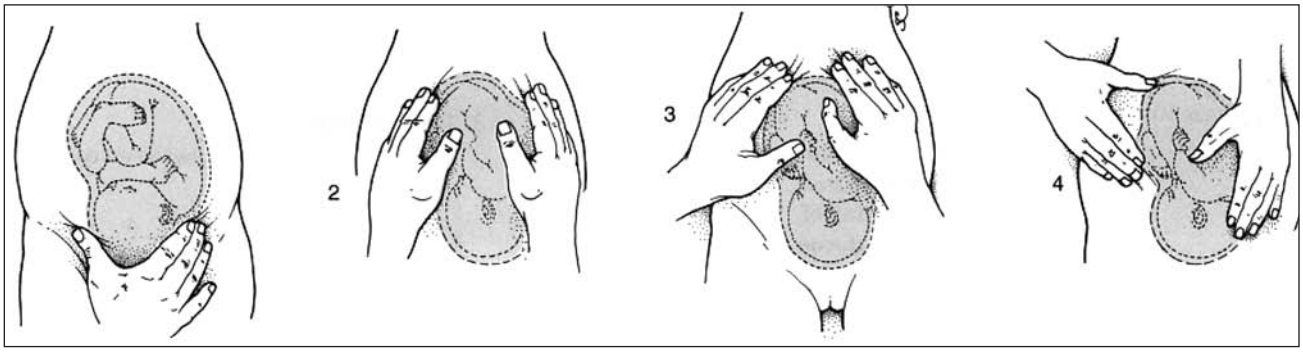

● Steps of Leopold's maneuvers.

Evaluate **fetal heart rate** by quadrant, location, and rate	120–160 beats/min	>160 or <120: may indicate fetal distress. *Notify physician*
Check for presence of **edema**	In lower extremities toward end of pregnancy	In upper extremities and face: may indicate preeclampsia

Assessment	Normal	Abnormal
Evaluate **urine** (clean catch midstream)	Negative for sugar, protein, and albumin	Positive for sugar: may indicate sub-clinical or gestational diabetes Positive for protein and/or albumin: may indicate preeclampsia
Evaluate **levels of discomfort**		
Intrapartum Assessment		
Assess for **lightening** and **dropping** (the descent of the presenting part into the pelvis)	Several days to 2 weeks before onset of labor Multipara: may not occur until onset of labor Relief of shortness of breath and increase in urinary frequency	No lightening or dropping: may indicate disproportion between fetal presenting part and maternal pelvis
Check if **mucous plug** has been expelled from cervix	Usually expelled from cervix prior to onset of labor	
Assess for **"bloody show"**	Clear, pinkish, or blood-tinged vaginal discharge that occurs as cervix begins to dilate and efface	
Assess for **ruptured membranes**		
Time water breaks	Before, during, or after onset of labor	Breech presentation: frank meconium or meconium staining
Color of **amniotic fluid**	Clear, straw color	Greenish-brown: indicates meconium has passed from fetus, possible fetal distress Yellow-stained: fetal hypoxia 36 hours or more prior to rupture of membrane or hemolytic disease
Quantity of amniotic fluid	Normal is 500 to 1000 mL of amniotic fluid, rarely expelled at one time	**Polyhydramnios**—excessive amniotic fluid over 2000 mL Observe newborn for congenital anomalies: craniospinal malformation, orogastrointestinal anomalies. Down's syndrome, and congenital heart defects **Oligohydramnios**—minimal amniotic fluid, less than 500 mL Observe newborn for malformation of ear, genitourinary tract anomalies, and renal agenesis
Odor of fluid	No odor	Odor may indicate infection; deliver within 24 hours
Fetal heart rate	120–160 beats/min	Decreased: indicates fetal distress with possible cord prolapse or cord compression
	Regular rhythm	Accelerated: initial sign of fetal hypoxia Absent: may indicate fetal demise
Labor and Delivery Assessment		
Evaluate Contractions		
Frequency: from start of one contraction to start of next	3–5 minutes between contractions	Irregular contractions with long intervals between: indicates false labor

(continued)

OBSTETRICAL ASSESSMENT (*continued*)

Assessment	Normal	Abnormal
Duration: from beginning of contraction to time uterus begins to relax	50–90 seconds	>90 seconds: uterine tetany; stop oxytocin if running
Intensity (strength of contraction): measured with monitoring device	Peak 25 mm Hg End of labor may reach 50–75 mm Hg	>75 mm Hg: uterine tetany or uterine rupture
First-Stage		
Latent phase (0–4 cm dilation)	0–3 to 4 cm; average 6.4 hrs	Prolonged time in any phase: may indicate poor fetal position, incomplete fetal flexion, cephalopelvic disproportion, or poor uterine contractions
Active phase (4–8 cm)		
Transitional phase (8–10 cm)	Length of time varies—may be 1–2 hours	If total labor <3 hours: indicates precipitous labor, increasing risk of fetal complications, or maternal lacerations and tears
Assess for **bloody show**		
Observe for presence of **nausea or vomiting**		
Assess **perineum**	Beginning to bulge	
Evaluate **urge to bear down**		Often uncontrolled Multipara: can cause precipitous delivery "Panting" (can be controlled until safe delivery area established)
Second stage (10 cm to delivery)	Primipara: up to 2 hours Multipara: several minutes to 2 hours	>2 hours: increased risk of fetal brain damage and maternal exhaustion
Assess for **presenting part**	Vertex with ROA or LOA presentation	Occiput posterior, breech, face, or transverse lie
Assess **caput** (infant head) Multipara: move to delivery room when caput size of dime Primipara: move to delivery room when caput size of half dollar	Visible when bearing down during contraction	"Crowns" in room other than delivery room: delivery imminent (do not move client)
Assess **fetal heart rate** Bradycardia, drop of 20 beats/min below base line (↓120 beats/min) Tachycardia, increase in FHR over 160 beats/min for 10 min	120–160/min	Decreased: may indicate supine hypotensive syndrome (turn client on side and take again) Hemorrhage (check for other signs of bleeding: notify physician) Increased or decreased: may indicate fetal distress secondary to cord progression or compression (place client in Trendelenburg or knee–chest position; give oxygen if necessary; inform physician)
Evaluate **fetal heart rate tracing**	Short-term variability is present Long-term variability ranges from 3–5 cycles/min	Absence of variability (no short term or long term present) Severe variable decelerations (fetal heart rate <70 for longer than 30–45 seconds with decreasing variability)

Assessment	Normal	Abnormal
Deceleration	Early deceleration (10–20 beat drop) Recovery when acme contraction passes—often not serious	Monitor closely—distinguish from late deceleration (10–20 beat decrease with hypertonic contraction); leads to fetal distress
Variable deceleration; decrease in FHR, below 120/min Loss of beat-to-beat variation	Mild; may be within normal parameters—continue to monitor If continues less than 15 minutes, no problem apparent	Cord compression—may result in fetal difficulty Late deceleration pattern occurs—monitor for hypertonic contraction; leads to total distress.
Evaluate **breathing**	Controlled with contractions	Heavy or excessive: may lead to hyperventilation and/or dehydration
Evaluate **pain** and **anxiety**	Medication required after dilated 4–5 cm unless using natural childbirth methods	Severe pain early in first stage of labor: inadequate prenatal teaching, backache due to position in bed, uterine tetany
Third stage (from delivery of baby to delivery of placenta)	Placental separation occurs within 30 minutes (usually 3–5 min)	Failure of placental separation Abnormality of uterus or cervix, weak, ineffectual uterine contraction, tetanic contractions causing closure of cervix >3 hours: indicates retained placenta
Fourth stage (first hour postpartum)		Mother in unstable condition (hemorrhage usual cause) Highest risk of hemorrhage in first postpartum hour
Temperature	36.5°C–37.5°C	>37.5°C: may indicate infection Slight elevation: due to dehydration from mouth breathing and NPO
Pulse	Pulse: 60–100	Increased: may indicate pain or hemorrhage
Respiration	Respirations: 12–22	
Blood pressure	Blood pressure: 120–140/80	Increased: may indicate anxiety, pain, or posteclamptic condition Decreased: hemorrhage
Postpartum Assessment		
Assess **vital signs** every 15 minutes for 1 hour, every 30 minutes for 1 hour, every hour for 4 hours, every 8 hours, and as needed	Pulse may be 45–60/min in stage 4 Pulse to normal range about third day	Decreased BP and increased pulse: probably postpartum hemorrhage Elevated temperature >38°C indicates possible infection Temperature elevates when lactation occurs
Assess **fundus** every 15 minutes for 1 hour, every 8 hours for 48 hours, then daily	Firm (like a grapefruit) in midline and at or slightly above umbilicus Return to prepregnant size in 6 weeks: descending at rate of 1 fingerbreadth/day	Boggy fundus: immediately massage gently until firm; report to physician and observe closely; empty bladder; medicate with oxytocin if ordered Fundus misplaced 1–2 fingerbreadths from midline: indicates full bladder (client must void or be catheterized)

(continued)

OBSTETRICAL ASSESSMENT (*continued*)

Assessment	Normal	Abnormal
Assess **lochia** every 15 minutes for 1 hour, every 8 hours for 48 hours, then daily		
Color	3 days postpartum: dark red (rubra) 4–10 days postpartum: clear pink (serosa) 10–21 days postpartum: white, yellow brown (alba)	Heavy, bright-red: indicates hemorrhage (massage fundus, give medication on order, notify physician) Spurts: may indicate cervical tear No lochia: may indicate clot occluding cervical opening (support fundus; express clot)
Quantity	Moderate amount, steadily decreases	Foul: may indicate infection
Odor	Minimal	
Assess **breasts** and **nipples** daily	Days 1–2: soft, intact, secreting colostrum Days 2–3: engorged, tender, full, tight, painful Day 3+: secreting milk Increased pains as baby sucks: common in multiparas	Sore or cracked (clean and dry nipples; decrease breast-feeding time; apply breast shield between feeding) Milk does not "let down": help client relax and decrease anxiety; give glass of wine or beer if not culturally, religiously, or otherwise contraindicated
Assess **perineum** daily	Episiotomy intact, no swelling, no discoloration	Swelling or bruising: may indicate hematoma
Assess **bladder** every 4 hours	Voiding regularly with no pain	Not voiding: bladder may be full and displaced to one side, leading to increased lochia (catheterization may be necessary)
Assess **bowels**	Spontaneous bowel movement 2–3 days after delivery	Fear associated with pain from hemorrhoids
Assess mother–infant **bonding**	Touching infant, talking to infant, talking about infant	Refuses to touch or hold infant
Evaluate **Rh-negative status**	Client does not require RhoGAM	RhoGAM administered
Maternal History: Definition of Terms		
Abortion: pregnancy loss before fetus is viable (usually <20 weeks or 500 g)	*Multigravida:* refers to second or any subsequent pregnancy	*Nullipara:* refers to female who has never carried pregnancy to viable age for fetus
Gravida: any pregnancy, including present one	*Para:* past pregnancies that continued to viable age (20 weeks); infants may be alive or dead at birth	*Multipara:* refers to female who has given birth to two or more viable infants; either alive or dead
Primigravida: refers to first-time pregnancy	*Primipara:* refers to female who has delivered first viable infant; born either alive or dead	

NEWBORN ASSESSMENT

Assessment	Normal	Abnormal
Skin Assessment		
Note skin **color, pigmentation,** and **lesions**	Pink Mongolian spots	Cyanosis, pallor, beefy red Petechiae, ecchymoses, or purpuric spots: signs of possible hematologic disorder

Assessment	Normal	Abnormal
	Capillary hemangiomas on face or neck	Café au lait spots (patches of brown discoloration): possible sign of congenital neurological disorder Raised capillary hemangiomas on areas other than face or neck
	Localized edema in presenting part	Edema of peritoneal wall
	Cheesy white vernix	Poor skin turgor: indicates dehydration
	Desquamation (peeling off)	Yellow discolored vernix (meconium stained)
	Milia (small white pustules over nose and chin)	Impetigo neonatorum (small pustules with surrounding red areas)
	Jaundice after 24 hours; gone by second week	Jaundice at birth or within 12 hours Dermal sinuses (opening to brain) Holes along spinal column Low hairline posteriorly: possible chromosomal abnormality Sparse or spotty hair: congenital goiter or chromosomal abnormality
Note color of **nails**	Pink	Yellowing of nail beds (meconium stained)
Note **muscle strength/tone**	Strong, tremulous	Flaccid, convulsions Muscular twitching, hypertonicity
Head and Neck Assessment		
Note **shape of head**	Fontanels: anterior open until 18 months; posterior closed shortly after birth	Depressed fontanels indicate dehydration; closed or bulging indicate congenital anomalies; full or bulging indicate edema or increased ICP Cephalohematoma that crosses the midline Microcephaly and macrocephaly
Assess **eyes**	Slight edema of lids	Purulent discharge Lateral upward slope of eye with an inner epicanthal fold in infants not of Asian descent Exophthalmos (bulging of eyeball): may be congenital anomaly, sign of congenital glaucoma or thyroid abnormality Enophthalmos (recession of eyeball): may indicate damage to brain or cervical spine
	Pupils equal and reactive to light by 3 weeks of age	Constricted pupil, unilateral dilated fixed pupil, nystagmus (rhythmic nonpurposeful movement of eyeball): continuous strabismus
	Intermittent strabismus (occasional crossing of eyes)	
	Conjunctival or scleral hemorrhages	Haziness of cornea
	Symmetrical light reflex (light reflects off each eye in the same quadrant): sign of conjugate gaze	Absence of red reflex; asymmetrical light reflex

(continued)

NEWBORN ASSESSMENT (*continued*)

Assessment	Normal	Abnormal
Note **placement of ears,** shape and position		
The top of the ear should be on an imaginary line from the edge of the eye		Low-set ears: may indicate chromosomal or renal system abnormality
Assess **nose**	Discharge, sneezing	Thick, bloody nasal discharge
Assess **mouth**	Sucking, rooting reflexes	Cleft lip, palate
	Retention cysts	Flat, white nonremovable spots (thrush)
	Occasional vomiting	Frequent vomiting: may indicate pyloric stenosis
		Vomitus with bile: fecal vomiting
		Profuse salivation: may indicate tracheoesophageal fistula
Assess **neck**	Tonic neck reflex (Fencer's position)	Distended neck veins
		Fractured clavicle
		Unusually short neck
		Excess posterior cervical skin
		Resistance to neck flexion
Assess **cry**	Lusty cry	Weak, groaning cry: possible neurological abnormality
		High-pitched cry: newborn drug withdrawal (may occur 6–12 months after birth); hoarse or crowing inspirations; catlike cry: possible neurological or chromosomal abnormality
Chest and Lung Assessment		
Assess **chest**	Circular	Depressed sternum
	Enlargement of breasts	Retractions, asymmetry of chest movements: indicates respiratory distress and possible pneumothorax
	Milky discharge from breasts	
Assess **respirations/lungs**	Abdominal respirations	Thoracic breathing, unequal motion of chest, rapid grasping or grunting respirations, flaring nares
	Respiration rate: 30 to 50	Deep sighing respirations
	Respiration movement irregular in rate and depth	Grunt on expiration: possible respiratory distress
	Resonant chest (hollow sound on percussion)	Hyper-resonance of chest or decreased resonance
Heart Assessment		
Assess the **rate, rhythm,** and **murmurs** of the heart	Rate: 100–160 at birth; stabilizes at 120–140	Heart rate >200 or <100
	Regular rhythm	Irregular rhythm
	Murmurs: significance cannot usually be determined in newborn	Dextrocardia, enlarged heart
Abdomen and Gastrointestinal Tract Assessment		
Assess the **abdomen**	Prominent	Distention of abdominal veins: possible portal vein obstruction
Assess the **gastrointestinal tract**	Bowel sounds present	Visible peristaltic waves
		Increased pitch or frequency: intestinal obstruction

Assessment	Normal	Abnormal
		Decreased sounds: paralytic ileus
		Distention of abdomen
	Liver 2 to 3 cm below right costal margin	Enlarged liver or spleen
	Spleen tip palpable	
		Midline suprapubic mass: may indicate Hirschsprung's disease
	Umbilical cord with one vein and two arteries	One artery present in umbilical cord: may indicate other anomalies
	Soft granulation tissue at umbilicus	Wet umbilical stump or fetid odor from stump
Genitourinary Tract Assessment		
Assess **kidneys and bladder**	May be able to palpate kidneys	Enlarged kidney
	Bladder percussed 1 to 4 cm above symphysis pubis	Distended bladder; presence of any masses
Assess the **genitalia**	Edema and bruising after delivery	Inguinal hernia
	Unusually large clitoris in females a short time after birth	Ambiguous genitalia (chromosomal abnormality)
	Vaginal mucoid or bloody discharge may be present in the first week	
Urethral orifice	Urethra opens on ventral surface of penile shaft	Hypospadias (urethra opens on the inferior surface of the penis)
		Epispadias (urethra opens on the dorsal surface of the penis)
		Ulceration of urethral orifice
Testes	Testes in scrotal sac or inguinal canal	Hydroceles in males
Spine and Extremities Assessment		
Assess the **spine**	Straight spine	Spina bifida, pilonidal sinus; scoliosis
Assess **extremities**		Asymmetry of movement
	Soft click with thigh rotation	Sharp click with thigh rotation: indicates possible congenital hip
		Uneven major gluteal folds: indicates possible congenital hip
		Polydactyly (extra digits on a hand or foot); syndactyly (webbing or fusion of fingers or toes)
Assess **anus and rectum**	Patent anus	Closed anus: no meconium

TABLE 11–3 APGAR SCORING

Sign	0	1	2
Heart rate	Absent	Slow (less than 100)	Over 100
Respiratory effort	Absent	Slow, irregular	Good, crying
Muscle tone	Flaccid	Some flexion of extremities	Active motion
Reflex irritability	No response	Cry	Vigorous cry
Color	Blue, pale	Body pink, extremities blue	Completely pink

APGAR scoring system is a method of evaluating a newborn's condition at 1 and 5 minutes after birth.

- Newborns who score 7–10 are considered free of immediate danger.
- Newborns who score 4–6 are moderately depressed.
- Newborns who score 0–3 are severely depressed.

Scores less than 7 at 5 minutes, repeat every 5 minutes for 20 minutes. Infant may be intubated unless 2 successive scores of 7 or more occur.

PEDIATRIC ASSESSMENT

Assessment	Normal	Abnormal
Measurements		
Measure **height** and **weight** and plot on a standardized growth chart	Height/weight proportional Sequential measurements: pattern follows normal growth curves	Height/weight below fifth percentile Sudden drop in percentile range of height and/or weight: possible sign of disease process or congenital problem Sudden and persistent increase (above 95th percentile)
Assess **temperature** (axillary or tympanic until 6 years of age)	Axillary 36.5°–37.5°C (97.7°F) Elevations following eating or playing not unusual Rectal 36.6°–37.2°C (97.8°F)	Temperature of 104°–105°F: corresponds roughly with 101°–102°F in an adult Large daily temperature variations Hypothermia: usually result of chilling
Measure **circumference of head and chest**		
Examine or check circumferences when child is less than 2 years old Compare measurements with standardized charts	Head at birth: about 2 cm greater than chest During first year: equalization of head and chest After 2 years: rapid growth of chest; slight increase in size of head	Increase in head circumference greater than 2.5 cm per month: sign of hydrocephalus
Assess **pulse** apically	Birth–1 year: 100–180 1 year: 80–150 2 years: 80–130 3 years: 80–120 Over 3 years: 70–110	Pulse over 180 *at rest* after first month of life: cardiac or respiratory condition Inability to palpate or very weak femoral and pedal pulses: possible coarctation of the aorta
Assess **respirations**	Birth: 30–50 6 years: 20–25 Puberty: 14–16 (Young children have abnormally high respiration rate with even slight excitement)	Consistent tachypnea: usually a sign of respiratory distress Respiratory rate over 100; lower respiratory tract obstruction Slow rate: may be sign of CNS depression
Assess **blood pressure**	Birth: 55–60/80–90 1 year: 90–60 Rise in both pressures: 2–3 points per year of age Adult level reached at puberty	Elevated blood pressure in upper extremities *and* decrease in lower extremities: coarctation of aorta Narrowed pulse pressure (normal or elevated diastolic with lowered systolic; less than 30 points difference between systolic and diastolic readings): possible sign of aortic or subaortic stenosis or hypothyroidism Widened pulse pressure: possible sign of hyperthyroidism
Appearance		
Observe **general appearance**	Alert, well-nourished, comfortable, responsive	Lethargic, uncomfortable, malnourished, gross anomalies, dull
Listen to **voice and cry**	Strong, lusty cry	Weak cry, low- or high-pitched cry: may indicate neurological problem or chromosomal abnormality

Assessment	Normal	Abnormal
		Stridor: possible upper airway edema or obstruction or hoarse cry
	Facial expression animated	Expressionless, unresponsive
	No indications of pain	Doubling over, rubbing a body part, general fretfulness, irritability
Assess presence of **odor**	No odor	Musty odor: sign of phenylketonuria, diphtheria Odor of maple syrup: may be maple syrup urine disease Odor of sweaty feet: one type of acidemia Fishy odor: may be metabolic disorder Acetone odor: acidosis, particularly diabetic ketoacidosis
Skin Assessment		
Assess **pigmentation**	Usually even Pigmented nevi common Large, flat, black and blue areas over sacrum, buttocks (mongolian spots)	Multiple cafe au lait spots: possible neurofibromatosis Cyanosis Jaundice Pallor
Assess **lesions**	Usually none Adolescence: acne	Erythematous lesions Multiple macules, papules, or vesicles Petechiae and ecchymoses: may indicate coagulation disorder
Assess **signs/symptoms of abuse**	None present	Hives (allergy) Subcutaneous nodules: may indicate juvenile rheumatoid arthritis Any unexplained bruises, welts, scars, burn marks, rope marks, failure to thrive, x-ray findings of multiple bone injuries, passive, noncommunicating child
Note **consistency of skin**	Good turgor Smooth and firm Check fontanel in infant	Poor turgor Dryness Edema Lack or excess of subcutaneous fat: sign of malnutrition or excess nutrition (obesity)
Assess **nails**	Nailbeds: normally pigmented Good nail growth	Cyanosis Pallor Capillary pulsations Pitting of the nails: possible sign of fungal disease or psoriasis Broad nailbeds: possible sign of Down's syndrome or other chromosomal abnormality
Assess **hair** (consistency appropriate to ethnic group)	No excessive breaking Consistent growth pattern	Dry, coarse, brittle hair: possible sign of hypothyroidism Alopecia (loss of hair): may be psychosomatic or due to drug therapy

(continued)

PEDIATRIC ASSESSMENT (*continued*)

Assessment	Normal	Abnormal
		Unusual hairiness in places other than scalp, eyebrows, and lashes: may indicate hypothyroidism, vitamin A poisoning, chronic infections, reaction to Dilantin therapy
		Tufts of hair over spine or sacrum: may indicate site of spina bifida occulta or spina bifida
		Absence of the start of pubic hair during adolescence: possible hypothyroidism, hypopituitarism, gonadal deficiency, or Addison's disease
Assess **lymph nodes**	Nontender, movable, discrete nodes up to 3 mm in diameter in occipital, postauricular, parotid, sub-maxillary, sublingual, axillary, and epitrochlear nodes	Tender or enlarged nodes: may be sign of systemic infection
	Up to 1 mm in diameter inguinal and cervical nodes	
Head and Neck Assessment		
Assess **scalp**	Usually without lesions	Ringworm, lice
Assess frontal and maxillary **sinuses**	Nontender	Tenderness: indicative of inflammatory process
		Seborrheic dermatitis
Assess **face**	Symmetrical movement	Asymmetry: signs of facial paralysis
		Twitching: could be due to psychosomatic causes; vitamin/mineral deficiency
Evaluate the eyes		
Gross screening of vision	With younger child, ability to focus and follow movement and to see objects placed a few feet away	Inability to follow movement or to see objects placed a few feet away
Snellen chart		
Sclerae	Completely white	Yellow sclera: sign of jaundice
		Blue sclera: may be normal or indicative of osteogenesis imperfecta
Placement in eye socket	Normally placed	Exophthalmos (protrusion of eyeball)
		Enophthalmos (deeply placed eyeball)
Iris	At rest: upper and lower margins of iris visible between the lids	Setting sun sign (iris appears to be beneath lower lid): if marked, may be sign of increased intracranial pressure or hydrocephalus
Movement	In newborn, intermittent strabismus or nystagmus	Fixed strabismus or intermittent strabismus continuing after 6 months of age: indication of muscle paralysis or weakness
		Involuntary, repetitive oscillations of one or both eyes: normal with *extreme* lateral gaze

Assessment	Normal	Abnormal
		Nystagmus: may be cerebellar dysfunction indicative of use of certain drugs (anticonvulsants, barbiturates, alcohol)
Eyelids	Fully covers eye Fully raised on opening	Ptosis of eyelid: may be an early sign of a neurological disorder Sty
Conjunctiva	Clear	Inflammation (conjunctivitis) Hemorrhage Stimson's lines (small red transverse lines on conjunctiva)
Cornea	Clear	Opacity: sign of ulceration Inflammation Redness
Discharge	Tears	Purulent discharges: note amount, color, consistency (bacterial conjunctivitis)
Pupils	Round, regular Clear, equal Brisk reaction to light Accommodation reflex (ability of lens to adjust to objects at different distances)	Sluggish or asymmetrical reaction to light: indicates intracranial disease Lack of accommodation reflex
Lens	Clear	Opacities (cataracts)
Evaluate the **ears**		
Sinuses	No abnormality	Small holes or pits anterior to ear: may be superficial but could indicate the presence of a sinus leading into brain
Position	Top of ear above level of eye	Top of ear below level of eye: associated with some congenital defects
Discharge	None	Discharge: note color, odor, consistency, and amount
Hearing	In infant: turning to sound In older child: responds to whispered command	Diminished hearing in one or both ears
Assess the **nose**	No secretions	Secretions: note characteristics Any unusual shape or flaring of nostrils
	Breathing through nose	Breathing through mouth
Assess the **mouth**		Circumoral pallor: possible sign of cyanotic heart disease, scarlet fever, rheumatic fever, hypoglycemia; also seen in other febrile diseases Asymmetry of lips: seen in nerve paralysis
	Intact palate	Cleft palate
	Teeth in good condition In older child presence of permanent teeth	Delayed appearance of deciduous teeth: may indicate cretinism, rickets, congenital syphilis, or Down syndrome; may also be normal

(continued)

PEDIATRIC ASSESSMENT (*continued*)

Assessment	Normal	Abnormal
		Poor tooth formation: may be seen with systemic diseases
		Green or black teeth: seen after iron ingestion or death of tooth
		Stained teeth: may be seen after prolonged use of tetracyclines
Assess the **gums**	Retention cysts in newborn	Inflammation, abnormal color, drooling, pus, tenderness
		Black line along gums: may indicate lead poisoning
Assess the **tongue**	Moves freely	Tremors on protrusion: may indicate chorea, hypothyroidism, cerebral palsy
		Protruding tongue—Down's syndrome
		White spots (thrush)
		Tongue-tie (frenulum)
	Pink, with conical, filiform nontender papillae	Strawberry tongue (scarlet fever)
Assess the **throat**	Tonsils normally enlarged in childhood	White membrane over tonsils (diphtheria)
		White pus on sacs, erythema (bacterial pharyngitis), tender: vitamin deficiencies, anemia
Assess the **larynx**	Normal vocal tones	Hoarseness or stridor: possible upper respiratory tract obstruction
Assess the **neck**	Short in infancy	
	Lengthens at 2–3 years	
	Trachea slightly right of midline	Trachea deviated to left or right: may indicate shift with atelectasis
Thyroid	Not enlarged	Enlarged: may be due to hyperactive thyroid, malignancy, goiter
Movement	Full lateral and upward/downward motion	Limited movement with pain: may indicate meningeal irritation, lymph node enlargement, rheumatoid arthritis, or other diseases
Lungs and Thorax Assessment		
Assess the **lungs**	Normally clear and equal breath sounds bilaterally	Presence of rhonchi, crackles, or wheezes
		Diminished breath sounds heard over parts of lung
	No retractions	Mild to severe intercostal or sternal retractions indicative of respiratory distress
	Symmetry of diaphragmatic movement	Asymmetry of movement (phrenic nerve damage)
Assess the **sputum**	None or small amount of clear sputum in morning	Thick, tenacious sputum with foul odor
		Blood-tinged or green sputum

Assessment	Normal	Abnormal
Assess the **breasts**	Slightly enlarged in infancy Generally slightly asymmetrical at puberty	Discharge or growth in male Masses (especially solid, fixed nonmobile) in older adolescent
Heart Assessment		
Assess **heart sounds**	S_1, S_2, S_3	S_4 indicates congestive heart failure
Assess **femoral pulses**	Strong	Weak
Note **edema**	None present	Edema—note location (initially periorbital) and duration, bulging fontanelles
Note **clubbing** of fingers	None present	Clubbing—congenital cyanotic heart defects; note location and duration
Note **murmurs**		Murmur grade three or higher is always abnormal No change in quality with positional changes
Note **cyanosis**	None normally present	Circumoral or peripheral cyanosis: indicates respiratory or cardiac disease (hypoxemia); congenital heart defects
Abdomen Assessment		
Assess **skin condition**	Soft	Hard, rigid, tender
Assess for **peristaltic motion**	Not visible	Visible peristalsis—may indicate pyloric stenosis (olive-shaped mass, palpable, in area of pyloris)
Assess **shape**	"Pot-bellied" toddlers Slightly protuberant in standing adolescent	Large protruding abdomen: may indicate pancreatic fibrosis, hypokalemia, rickets, hypothyroidism, bowel obstruction, constipation, inguinal hernias, unilateral or bilateral: observe for reducibility
	Umbilical protrusion	Umbilical hernia
Genitourinary Tract Assessment		
Assess **female genitalia**		
Discharge	Mucoid, no odor	Foul or copious discharge; any bleeding prior to puberty
Assess **male genitalia**	Orifice on distal end of penis	Hypospadias or epispadias (urethral orifice along inferior or dorsal surface)
Presence of urethral orifice		
Urethral opening		
Foreskin	Normal size Covers glans completely	Stenosis of urethral opening Foreskin incompletely formed ventrally when hypospadias present
Placement of testes	Descended testes	Undescended testes Enlarged scrotum
Signs of abuse	No signs	Bruises, welts, swelling, discharge, bleeding
Assess **urine output**	Full, steady stream of urine	Urine with pus, blood, or odor (infection) Excessive urination or nocturia: possible sign of diabetes

(continued)

PEDIATRIC ASSESSMENT (*continued*)

Assessment	Normal	Abnormal
Check **anus and rectum**	No masses or fissures present	Hemorrhoids, fissures, prolapse, pinworms Dark ring around rectal mucosa: may be sign of lead poisoning
Musculoskeletal Assessment		
Assess **extremities**	Coloration of fingers and toes consistent with rest of body	Cyanosis—indicates respiratory or cardiac disease, or hypothermia in newborn Clubbing of fingers and toes indicates cardiac or respiratory disease
	Quick capillary refill on blanching	Sluggish blood return on blanching indicates poor circulation
	Temperature same as rest of body	Temperature variation between extremities and rest of body indicates neurological or vascular anomalies
	Presence of pedal pulses	Absence of pedal pulses indicates circulatory difficulties
	No pain or tenderness	Presence of localized or generalized pain
	Straight legs after 2 years of age	Any bowing after 2 years of age may be hereditary or indicate rickets
	Broad-based gait until 4 years of age; feet straight ahead afterwards	Scissoring gait indicates spastic cerebral palsy Persistence of broad-based gait after 4 years of age indicates possible abnormalities of legs and feet or balance disturbance Any limp or ataxia
Assess **spine**	No dimples	Presence of dimple or tufts of hair indicates possible spina bifida
	Flexible	Limited flexion indicates central nervous system infections Hyperextension (opisthotonos) indicates brain stem irritation, hemorrhage, or intracranial infection
Have child bend forward at waist and check level of scapulae (scoliosis screening)	No lateral curvature or excessive anterior posterior curvature Scapulae at same height	Presence of lordosis (after age 2 years), kyphosis, or scoliosis
Assess **hips**		Asymmetrical thigh folds, clicks on adduction—hip dysplasia
Assess **joints**	Full range of motion without pain, edema, or tenderness	Pain, edema, or tenderness indicates tissue injury
Assess **muscles**	Good tone and purposeful movement Ability to perform motor skills approximate to development level	Decreased or increased tone Spasm or tremors may indicate cerebral palsy Atrophy or contractures

CHAPTER ADDENDUM

GERONTOLOGIC CONSIDERATIONS

HEAD AND NECK AND NEUROLOGIC SYSTEM

Physiologic Changes with Age

- Decreased speed of nerve conduction and delay in response and reaction time, especially with stress.
- Diminution of sensory faculties; decreased vision, loss of hearing, diminished sense of smell and taste, greater sensitivity to temperature changes with low tolerance to cold.
- Tooth loss.
- Poor dentition, inadequate chewing, poor swallowing reflex.
- Condition of teeth, gums, buccal cavity.
- Periodontal disease.

Taste sensation decreases.

- Chronic irritation of mucous membranes.
- Atrophy of up to 80% of taste buds.
- Loss of sensitivity of those on tip of tongue first: sweet and salt.
- Loss of sensitivity of those on sides later: salt, sour, bitter.

Assessment

- Facial symmetry.
- Poor reflex reactions.
- Level of alertness—presence of organic brain changes: memory impairment.
- Motor function—strength.

SKIN

Physiologic Changes with Age

Skin less effective as barrier.

- Decreased protection from trauma.
- Less ability to retain water.
- Decreased temperature regulation.

Skin composition changes.

- Dryness (osteotosis) due to decreased endocrine secretion.
- Loss of elastin.
- Increased vascular fragility.
- Thicker and more wrinkled on sun-exposed areas.
- Melanocyte cluster pigmentation.

Sweat glands.

- Decreased number and size.
- Decreased function of sebaceous glands.

Hair.

- General hair loss.
- Decreased melanin production.
- Facial hair increases in women.

Nails.

- More brittle and thick.

Assessment

Skin.

- Temperature, degree of moisture, dryness.
- Intactness, open lesions, tears, decubiti.
- Turgor, dehydration.
- Pigmentation alterations, potential cancer.
- Pruritus—dry skin most common cause.

Bruises, scars.

Condition of nails (hard and brittle).

- Presence of fungus.
- Overgrown or horny toenails, ingrown.

Condition of hair.

Infestations (scabies, lice).

Chest

Physiologic Changes with Age

Respiratory muscles lose strength and become rigid.

Ciliary activity decreases.

Lungs lose elasticity.

- Residual capacity increases.
- Larger on inspiration.
- Maximum breathing capacity decreases; depth of respirations decreases.

Alveoli increase in size, reduce in number.

- Fewer capillaries at alveoli.
- Dilated and less elastic alveoli.

Gas exchange is reduced.

- Arterial blood oxygen Pa_{O_2} decreases to 75 mm Hg at age 70.
- Arterial blood carbon dioxide Pa_{CO_2} unchanged.

Coughing ability is reduced—less sensitive mechanism.

More dependent on the diaphragm for breathing.

System less responsive to hypoxia and hypercardia.

Assessment

- Shape of chest excursion.
- Lung and breath sounds.
- Quality of cough, if present; sputum.

Rib cage deformity.

Dyspnea, hypoxia, and hypercarbia.

Breast—size, symmetry, contour.

- Presence of lumps.
- Size and shape of nipples.

HEART

Physiologic Changes with Age

Mitral and aortic valves thicken and become rigid.

Cardiac output decreases 1% per year after age 20 due to decreased heart rate and stroke volume.

Vessels lose elasticity.

- Less effective peripheral oxygenation.
- Position change from lying-to-sitting or sitting-to-standing can cause blood pressure to drop as much as 65 mm Hg.

Increased peripheral vessel resistance.

- Blood pressure increases: systolic may normally be 170 mm Hg, diastolic may normally be 95 mm Hg.
- Smooth muscle in arteries is less responsive.

Blood clotting increases.

Assessment

Heart sounds—murmurs.

Peripheral circulation, color, warmth.

- Apical pulse.
- Jugular vein distention.

Orthostatic hypotension.

- Dizziness.
- Fainting.

Edema.

Activity intolerance.

Dyspnea.

Transient ischemic attacks (TIAs).

ABDOMEN

Physiologic Changes with Age

Esophagus dilates, decreased motility.

Stomach.

- Hunger sensations decrease.
- Secretion of hydrochloric acid decreases.
- Emptying time decreases.

Peristalsis decreases and constipation is common.

Absorption function is impaired.

- Body absorbs less nutrients due to reduced intestinal blood flow and atrophy of cells on absorbing surfaces.
- Decrease in gastric enzymes affects absorption.

Hiatal hernia common (40–60% of elderly).

Diverticulitis common (40% over age 70).

Liver.

- Fewer cells, with decreased storage capacity.
- Decreased blood flow.
- Enzymes decrease.
- Increased risk for drug toxicity.

Impaired pancreatic reserve.

Decreased glucose tolerance.

Assessment

- Indications of possible hiatal hernia.
- Bowel distention.
- Bowel sounds.

GENITOURINARY TRACT

Physiologic Changes with Age

Kidneys.

- Smaller due to nephron atrophy.
- Renal blood flow decreases 50%.
- Glomerular filtration rate decreases 50%.
- Tubular function diminishes: less able to concentrate urine; lower specific gravity; proteinuria 1+ is common; blood urea nitrogen (BUN) increases 21 mg%.

Renal threshold for glucose increases.

Bladder.

- Muscle weakens.
- Capacity decreases to 200 mL or less, causing frequency.
- Emptying is more difficult, causing increased retention.
- Increased risk of incontinence.

Prostate enlarges to some degree in 75% of men over age 65; hypertrophy.

Menopause occurs by mean age of 50.

Perineal muscle weakens.

Vulva atrophies.

Vagina.

- Mucous membrane becomes dryer.
- Elasticity of tissue decreases, so surface is smooth.
- Secretions become reduced, more alkaline.
- Flora changes.

Sexuality.

- Older people continue to be sexual beings with sexual needs.
- No particular age at which a person's sexual functioning ceases.
- Frequency of genital sexual behavior (intercourse) may tend to decline gradually in later years, but capacity for expression and enjoyment continue far into old age.

Assessment

- Condition of skin—dehydration.
- Urinary output; blood in urine; color; specific gravity; prothrombin time (PT).
- Incontinence.
- Bladder distention.
- Genital assessment.

MUSCULOSKELETAL SYSTEM

Physiologic Changes with Age

Contractures.

- Muscles atrophy, regenerate slowly, strength diminishes.
- Tendons shrink and sclerose.

Range of motion of joints decreases.

- Lack of adequate joint motion, ankylosis.
- Slight flexion of joints.

Assessment

Mobility level.

- Ambulate with more difficulty.
- Limitation to movement.
- Muscle strength cramps.
- Gait becomes unsteady.

Presence of kyphosis.

Pain in joints.

MANAGEMENT GUIDELINES

Each state legislates a Nurse Practice Act for RNs and LVN/LPNs. Health care facilities are responsible for establishing and implementing policies and procedures that conform to their state's regulations. Verify the regulations and role parameters for each health care worker in your facility.

DELEGATION

- RNs must complete the admission assessment and document the findings. They cannot delegate this activity to anyone else on the team.
- LVN/LPNs may complete focus assessments each shift; however, any changes in assessment findings must be reported and verified with the RN.
- Unlicensed assistive-personnel may not perform assessments on clients.

COMMUNICATION NETWORK

- Changes in assessment data identified in report or in the client's chart must be reported to the appropriate nurse assigned to complete the focus assessment.
- LVN/LPNs delegated the responsibility to complete focus assessments on clients must have clear direction on what is essential information to report back. Remind the LVN/LPN they must verify with the RN any changes identified in the assessment.
- Remind LVN/LPNs that if there are any questions on the client status as a result of their assessment, they must notify the RN immediately.

CRITICAL THINKING STRATEGIES

SCENARIO 1

Mrs. Smiley has had a history of hypertension for several years. She has recently experienced an inability to use her right arm and leg and has lost ability to express herself. She has been admitted to your unit with the diagnosis of R/O left CVA (stroke) and has been placed on a continuous heparin IV drip.

1. Based on admitting data, make a judgment about what deviations from normal you would find in the physical examination.
2. List appropriate nursing diagnoses based on her physical state and immobility status (this affects virtually all systems).
3. In view of all these existing and potential problems, identify *priority* concerns (all are important concerns) for this client.
4. Develop a plan of care addressing these priority concerns.

SCENARIO 2

You are caring for a woman in labor and monitoring the fetal heart rate. You note that early deceleration has occured (a 10- to 20-beat drop in the fetal heart rate).

1. From these symptoms, indicate your priority intervention.
2. What would you conclude about the viability of the fetus?
3. What does this change in condition of the fetus imply?

NCLEX® REVIEW QUESTIONS

Unless otherwise specified, choose only one (1) answer.

1 The systematic approach the nurse should follow when auscultating a client's lungs is
1. Anterior to posterior.
2. Top to bottom.
3. Posterior to lateral to anterior.
4. Side to side.

2 The nurse suspects that a client has appendicitis. When assessing for rebound tenderness, the nurse should
1. Perform this assessment first.
2. Have the client take a deep breath.
3. Palpate deeply with quick release of pressure.
4. Have the client lie flat with legs extended.

3 A client comes into the clinic for evaluation of a burn injury from hot liquid. The lesions are flat and red. The nurse should document the presence of
1. Macules.
2. Wheals.
3. Vesicles.
4. Papules.

4 The nurse is assessing a client's deep tendon reflexes. When documenting a normal response, the nurse would chart
1. +1.
2. 0.
3. +2.
4. +4.

5 The cranial nerve that is assessed when testing for the "gag reflex" is the
1. XI accessory.
2. VII facial.
3. IX glossopharyngeal.
4. XII hypoglossal.

6 During a cardiac assessment, the S_1 heart sound can be heard best
1. At the second intercostal space.
2. By using the bell of the stethoscope.
3. Over the aortic area.
4. At the apex of the heart.

7 When assessing the lymph nodes in the neck, the nurse should instruct the client to
1. Raise the chin.
2. Lie in a supine position.
3. Swallow a sip of water.
4. Flex neck slightly.

8 Completing a physical assessment, the nurse is unable to palpate a peripheral pulse, the dorsalis pedis. The next intervention would be to
1. Notify the physician.
2. Examine the adjacent area.
3. Obtain a new Doppler.
4. Move on to the next area.

9 The urinary tract assessment includes checking the specific gravity of the client's urine to determine if it is within normal limits. The normal range of specific gravity is _____.

10 Suspecting that the client you are assessing may be exhibiting cognitive decline or dementia, which of the following statements would be appropriate?
1. How do you feel today?
2. What work did you do twenty years ago?
3. Who is the president of the United States?
4. Tell me about why you are in the hospital.